



## **Developing a Computer-based Information System to Improve the Diagnosis of Blood Anemia**

**تطوير نظام معلومات معتمداً على الحاسوب لتحسين تشخيص فقر الدم**

By

**Bashar Abdallah Issa Khawaldeh**

Supervisor

**Dr. Basim Alhadidi**

This Thesis is submitted to the Department of Computer Information Systems, Faculty of Information Technology, Middle East University in partial fulfillment for the requirements for the degree of Master Degree in Computer Information System.

**Department of Computer Information Systems**

**Faculty of Information Technology**

**Middle East University**

(May 2013)

**Amman – Jordan**

### نموذج إقرار تفويض

أنا بشار عبدالله عيسى الخوالده أفوض جامعة الشرق الأوسط بتزويد نسخ من رسالتي للمكتبات أو المؤسسات أو الهيئات أو الأفراد عند طلبها بهدف البحث العلمي وإثراءه بعيداً عن الاهداف التجارية وأدناه وقع عليه.



التوقيع:

٢٠١٣ / أيار / ٢٦

التاريخ:

### Authorization statement

I, **Bashar Abdallah Issa Khawaldeh** authorizing the Middle East University to supply a copy of my Thesis to libraries, establishments or individuals upon their request. It is understood that copying or publication of this thesis of financial gain shall not be allowed without my written permission.

Signature:



Date: *May . 26 . 2013*

### Examination Committee Decision

This dissertation entitled **“Developing a Computer-based Information System to Improve the Diagnosis of Blood Anemia”** was discussed and passed on May, 4, 2013.

#### Discussion Committee Members

#### Signature

Dr. Mohammed Al Masarweh      Chairman

  
.....

Dr. Hussein Al-Bahadili      Member

  
26/5/2013  
.....

Dr. Basim Alhadidi      Member and Supervisor

  
.....

## DECLARATION

I do hereby declare the present research work has been carried out by me under the supervision of Dr. Basim Alhadidi, and this work has not been submitted elsewhere for any other degree, fellowship or any other similar title.

Signature:

A handwritten signature in blue ink, consisting of a large, stylized loop at the top and a series of connected strokes below it.

Date: May, 26, 2013

## **ACKNOWLEDGMENTS**

I would like to thank my supervisor Dr. Basim Alhadidi for his support, encouragement, proofreading of thesis drafts, and helping me throughout my thesis, and so directing to the right track of Image processing. I thank the Information Technology Faculty members at the Middle East University for Graduate Studies; I thank my father and my mother for their continued support during my study.

## **DEDICATION**

All praise belongs to Allah and all thanks to Allah.

I dedicate this work to Parents, brothers, sisters, relatives, friends, and to all those who helped, supported and taught me.

## Table of Contents

Developing a Computer- based Information System to Improve the Diagnosis of Blood Anemia .....	I
نموذج اقرار تفويض .....	II
Authorization Statement .....	III
Examination Committee Decision .....	IV
Declaration .....	V
Acknowledgments .....	VI
Dedication .....	VII
Table of Contents.....	VIII
List of Tables .....	XI
List of Charts .....	XII
List of Figures .....	XIII
List of Abbreviations .....	XV
Abstract .....	XVI
الملخص.....	XVII
1. Chapter One: Introduction.....	1
1.1 Overview .....	1
1.2 Problem Statement .....	2
1.3 Goal .....	3
1.4 The Objectives .....	3
1.5 Research Importance .....	4
1.6 Limitation .....	4
1.7 Thesis Structure .....	5



2. Chapter Two: Literature Survey and Related Work .....	6
2.1 Blood Anemia .....	6
2.1.1 Clinical Manifestation.....	7
2.1.2 Blood Smear Preparation, Staining and Examination .....	7
2.1.3 Abnormal Morphology of RBCs.....	9
2.1.4 Anemia Laboratory Diagnosis .....	13
2.1.5 Summary .....	22
2.2 Image Processing Techniques .....	23
2.3 Review of Previous Work .....	29
3. Chapter three: System Model Design and Implementation .....	32
3.1 Subsystem Model Design .....	32
3.1.1 Process Operations Representation .....	34
3.1.2 Graphical Representation of Processing .....	35
3.1.3 User's Interaction with the System Representation .....	36
3.1.4 Scenarios .....	37
3.2 System Application Phases .....	38
3.2.1 Image Acquisition and Read Image .....	42
3.2.2 Image Preprocessing .....	44
3.2.2.1 Handling Image Magnification .....	44
3.2.2.2 Creating Gray Scale Image .....	47
3.2.2.3 Image Enhancement Using IMADJUST.....	48
3.2.2.4 Creating Binary Image (Black & White) .....	49
3.2.2.5 Removing Small Objects.....	52
3.2.2.6 Regions Boundary Tracing.....	53
3.2.2.7 Removing Incomplete Objects at the Boundary of the Image .....	54
3.2.2.8 Removing Intersected Cells.....	56

3.2.2.9 Creating Binary Image Depending on Red Scale Image .....	57
3.2.3 Feature Extraction .....	58
3.2.4 Red blood Cells Classification .....	62
3.2.5 Results.....	69
4. Chapter Four: Results and Discussion .....	71
4.1 Comparison of this Work with Previous Work and Discussion .....	71
4.2 Results.....	75
4.3 Comparison of Classification: System versa Traditional .....	88
4.4 Experts Point View.....	89
5. Chapter Five: Conclusion & Future Work.....	91
5.1 Conclusion.....	91
5.2 Future Work .....	92
References .....	93

## List of Tables

Table (2.1) General Features of Hemolytic Disorders .....	17
Table (2.2) Some of MATLAB functions .....	24
Table (4.1) The result of tests were conducted on 12 images .....	75

## List of Charts

Table (4.1) Results Comparison of Classification: System verves Traditional Method .....	88
Table (4.1) The System Accuracy Rate .....	89

## List of Figures

Figure (2.1) Blood Smear Reading by Microscope .....	9
Figure (2.2) Morphology Abnormal Red Blood Cells .....	13
Figure (2.3) Boundaries of Objects and the Holes .....	28
Figure (3.1) Subsystem and Component Design .....	32
Figure (3.2) Data Flowchart .....	34
Figure (3.3) Data Flow Diagram .....	35
Figure (3.4) Use Case. ....	36
Figure (3.5 ) Sequence of Main Scenario .....	37
Figure (3.6) Collaboration of Main Scenario .....	38
Figure (3.7) System Application Phases .....	39
Figure (3.8) RBCs Classification .....	40
Figure (3.9) Red Blood Cells Classification Conditions .....	41
Figure (3.10) RGB-Image of the Blood Smear.....	43
Figure (3.11) Gray Scale Image after Using (rgb2gray) Function .....	47
Figure (3.12) Image Enhancement Using (imadjust) Function.....	48
Figure (3.13) Part Matrix for Gray Scale Image .....	49
Figure (3.14) Part Matrix for Binary Image .....	49
Figure (3.15) Binary Image Using (im2bw) Function .....	50
Figure (3.16) Complementing Binary Image Using (imcomplement) Function .....	51
Figure (3.17) Binary Image after Removing Small Objects .....	53

Figure (3.18) Binary Image after Removing Incompletely Objects at the Boundary.....	55
Figure (3.19) Complementing Binary Image after Removing Intersected Cells .....	57
Figure (3.20) Circularity for the Region and Major/Minor Axis .....	59
Figure (3.21) Center Point for Bounding Box.....	60
Figure (3.22) Center Point for the Region.....	61
Figure (3.23) Results Screen .....	70
Figure (4.1) Macrocyte Identification. ....	76
Figure (4.2) Microcyte Identification. ....	77
Figure (4.3) Basophilic stippling Identification .....	78
Figure (4.4) Howell- Jolly Body Identification. ....	79
Figure (4.5) Nucleated and Teardrop Identification. ....	80
Figure (4.6) Reticulocytes Identification. ....	81
Figure (4.7) Sickle Cells Identification. ....	82
Figure (4.8) Spherocyte Identification. ....	83
Figure (4.9) Stomatocyte Identification. ....	84
Figure (4.10) Target Cells Identification. ....	85
Figure (4.11) Teardrop Cells Identification. ....	86
Figure (4.12) Elliptocytes Identification. ....	87

## List of Abbreviations

RBC's	Red Blood Cells
WBC's	White Blood Cells
HSM	Hospital Management System
BM	Bone Marrow
HB	Hemoglobin
HCT	Hematocrit
MCV	Mean Corpuscular Volume
MCH	Mean Corpuscular Hemoglobin
MCHC	Mean Cell Hemoglobin Concentration
RDW	Red Distribution Width
HA	Hemolytic Anemia
HS	Hereditary Spherocytosis

## **ABSTRACT**

Design and implementation of a computer- based information system by utilizing a developed methodology is presented in this thesis. This methodology includes a set of procedures and processes to analyze blood smear images (image reading, preprocessing, feature extraction, RBCs classification, results and diagnosis).

Essentially an efficient method using the image processing technique (image enhancement, segmentation and feature extraction) has been constructed which can be used to analyze blood smear images taken by photomicroscope. Usually blood smear images contain red blood cells, white blood cells and platelets. In this work the method isolates and determines the type of all red blood cells in the smear which could be either normal or abnormal. Taking into consideration that abnormal red blood cells indicate to the associated blood anemia. Focus was directed to the process of classifying types of abnormal cells.

The system counts the overall red blood cells and calculates percentage of different types of counted abnormal cells (macrocyte, target cell, howel-jolley body, sickle cell, elliptocyte, tear drop, spherocyte, stomatocyte, basophilic stippling, reticulocyte, microcyte, and nucleated RBCs). The existence of different abnormal types and the related percentages indicate to the type of blood anemia. As a result and to testing the accuracy of these methods (the traditional method and this system) were applied to the same blood samples which contain 597 cells. Results of the two methods were close enough and acceptably comparable. The accuracy of this method is 83%.



## الملخص

تقدم هذه الرسالة تصميم وتطبيق لنظام معلومات مبني على الكمبيوتر باستخدام منهجية حديثة, هذه المنهجية تتضمن العديد من الاجراءات والمراحل لتحليل صور مسحات الدم (قراءة الصور, الإعداد للتحليل, التصنيف, النتائج والتشخيص).

جوهريا تم انشاء تقنية فعالة باستخدام تقنيات معالجة الصور (تحسين الصور, تقطيع الصور, استخراج الخصائص) لتحليل الصور والتي من الممكن استخدامها لتحليل صور مسحات الدم المأخوذة بواسطة الفوتوميكروسكوب, في العادة تحتوي صور مسحات الدم على خلايا الدم الحمراء و البيضاء بالإضافة الى صفائح الدم, في هذا العمل تقوم التقنية بعزل وتحديد جميع خلايا الدم الحمراء في مسحة الدم والتي من الممكن ان تكون طبيعية أو غير طبيعية, مع الاخذ بعين الاعتبار ان خلايا الدم الحمراء غير الطبيعية تشير الى الانيميا, ركزت الدراسة على تصنيف انواع الخلايا غير الطبيعية.

تقوم هذه التقنية بعد العدد الكلي لخلايا الدم الحمراء و ثم حساب النسبة المئوية للأنواع المختلفة من خلايا الدم غير الطبيعية (خلايا كبيرة, هدفية, ذات اجسام هولجولي, منجلية, اهليجية, على شكل دمع, كروية, ذات فجوة تشبه الفم, منقطه, شبكية, صغيرة, منواة) ان وجود انواع مختلفة من خلايا الدم غير الطبيعية ونسبها المئوية يشير الى نوع الانيميا. كنتيجة لفحص دقة الأدوات المستخدمة (الطريقة التقليدية و هذا النظام) طبقت الأدوات على نفس عينات الدم و التي

تحتوي على 597 خلية وتبين ان الطريقتين متقاربتين جدا ويمكن المقارنة بينهما. دقة هذا النظام

83% .

# **Chapter One**

## **Introduction**

### **1.1 Overview**

The widespread of computers and the emergence of new information systems have played a leading role in the development of modern software. The use of such software has widely spread, especially in the fields of Biomedical Science, where new information systems have been created to represent creative and pioneering capabilities as far as application and usages are concerned. The aim of this work is to show the importance of computer – based information system using image processing at the fields of Biomedical Sciences making use of the intelligence and speed of computer techniques to extract information of great significance to physicians and to specialists.

The early diagnoses types of anemia could assist in quick treatment; blood anemia is a common blood disease that affects a range of people by prohibiting them from enjoying a normal life, especially children and women. This anemia is due to lack of pigment, which imparted a red color of hemoglobin, a substance found in red blood cells, carry and distribute oxygen to all body cells. Red Blood Cells (RBC) image analysis in blood smear is very important to determine the type of anemia; a typical blood smear consists of white blood cells (WBC), RBC and platelets.

The goal of classifying of the red blood cells using image processing is to locate morphological features of RBC's in the blood smear (Sinh, & Ramakrishnan, 2002). This will facilitate their further processing to classify RBC's in Normal Cells and abnormal Cells (Hypo chromic, Microcytic, Target cell, Nucleated RBC's, polychromatic and sickle cells). The analyzed cells in the blood smear will provide useful information about anemia.

The peripheral blood film first prepared in the Laboratory, and after professionally stained the analyst used to read and analyze the image of blood film under microscope with precise lenses.

## **1.2 Problem Statement**

A stained smear is examined to determine the percentage of each type of leukocyte (WBCs) present and assess the Erythrocyte (RBCs) and platelet morphology. but in this work we concentrate on Erythrocyte which is examined by analyst (someone with experience in analyzing blood) using a microscope to see the blood cells on blood smear then we can identify if a person has a type of anemia or not. This traditional method suffers from basic problems such as:

- It consumes of too much time and effort .
- It needs a blood expert analyst.
- Disease is determined based on approximate results rather than on exact ones.

In this work a computer-based information system has been developed using image processing to improve diagnosis of blood anemia.

### **1.3 Goal**

The main goal of this thesis is to automate the manual process of identifying the type of anemia; this work will basically depend on making use of image processing.

At present, identifying Anemia results is approximate, susceptible to human errors, relatively slow and must be done by a specialized analyst. Using the proposed approach does not necessarily needs an expert analyst; on the other hand, the end results should be exact rather than approximate, less susceptible to human errors and considerably faster.

### **1.4 The Objectives**

The main objectives of this work can be summarized as follow:

- 1- The classification of blood cells in a blood smear.
- 2- The analysis of red blood cells by morphological features.
- 3- Calculating numbers of red cells, the number of abnormal cells (microcytic, hypochromic, target cells.... etc) and the percentage between them.
- 4- Identification types of anemia if it exists.

## 1.5 Research Importance

The need to save both time and effort of patients and physicians may well be the driver behind developing more research in utilizing image processing in this regard, saving time and faster diagnoses lead to determining the right cure which surely stops the suffering of the affected person.

By automation, the need for specialized trained staff is not essential, less effort is required and possible human mistakes will not affect the output noticeably, this will have a great effect on the exactness of the result.

Briefly, the motivation is to work in favor of both patients and people taking care of those patients regarding reducing time for diagnose, reducing the effort and cost until achieving more exact output. The current developed computer technologies available provide additional motive to focus more on researches in the favor of biomedical sciences.

## 1.6 Limitation

The diagnosis of blood anemia using the proposed computer-based information system will be limited to one or more of the following factors:

- This system as other systems suffered certain limitations like previous systems, overlapping cells were removed. This may eliminate some important diagnostic features that those cells would have possessed. Furthermore, cells lying at the boundaries were also omitted.

- The quality of the blood smear presented depends on how professionally was the smear prepared. For instance a clean high quality slide, the shape and the thickness of the sample on the slide, as well as the staining method that could affect the quality of the analyzed image input.
- The quality of the blood sample images acquired from using a high resolution digital camera mounted on a microscope, various magnification factors could affect the quality of the images, like color depth, images sizes, the hygienic environment while taking the image in a Lab room, camera pixel values.

## **1.7 Thesis Structure**

The thesis is divided into five chapters, chapter one presents the main theme of this thesis, the motivation and problem statement, chapter two reviews presents literature review that summarizes the most recent and related work, chapter three - presents a detailed description of the system approach and implementation, chapter four - the Results and discussion. Finally in chapter five, conclusions are drawn and recommendations for future works were presented.

## **Chapter Two**

### **Related Work and Literature Review**

#### **2.1 Blood Anemia**

Comprehensive reviews of published literature suggest that about 30% of the world population is anemic. Worldwide, about half of all cases of anemia are attributable to iron deficiency anemia. Iron deficiency is the most common nutritional deficiency in the world with anemia complicating about one third of these cases. Anemia accounts for a significant morbidity and mortality burden in Africa and certain parts of Asia, reflecting the importance of precise identification and management of its various types. (Ciesla, 2007)

Anemia affects both sexes, all ages, races and ethnic groups, with certain types of anemia more prevalent in some geographic and ethnic groups than other. Anemia can be either inherited or acquired. Inheritance can be in autosomal dominant (like hereditary spherocytosis), autosomal recessive (like sickle cell anemia). Acquired causes include exposure to certain drugs, toxins, and infectious agents. Deficiency of certain elements or vitamins such as iron and vitamin B12 can also lead to anemia. (Turgeon, 2012)



### **2.1.1 Clinical Manifestation**

Anemia is most often recognized by abnormal laboratory screening test. Less commonly, patients present with signs and symptoms related to anemia. The symptoms of anemia depend on its severity and the rapidity of its onset. A severe anemia with gradual onset can go unnoticed whereas a one that is less severe but of acute onset can lead to dramatic hemodynamic instability. Symptoms associated with moderate anemia include pallor, fatigue, loss of stamina, breathlessness, and palpitations (Fauci, et al., 2008).

Certain disorders are commonly associated with anemia like rheumatoid arthritis. In these situations patients more often present with symptoms of the underlying disease more than that of anemia. Over all, anemia can be classified into:

1. That caused by marrow production defect.
2. RBC maturation defect.
3. Decrease RBC survival.

### **2.1.2 Blood Smear Preparation, Staining and Examination**

A stained smear of peripheral blood provides information about red blood cell, white blood cell, and platelet morphology and count. Increase in any of the normal leukocyte types and the presence of immature leukocytes or erythrocytes in peripheral blood are important diagnostically in a wide variety of inflammatory, infectious, and malignant disorders.

Erythrocyte abnormalities are clinically important in various types of anemia. When abnormal critical results are produced by the automated analyzer, the blood film should be made and evaluated to confirm the results.

A peripheral blood film analysis procedure includes three processes:

a) Spreading:

- 1- A small drop of EDTA anticoagulated blood is placed in the centerline of a slide about 1 cm from one end.
- 2- Place a spreader in front of the drop at an angle of  $30^{\circ}$  to the slide and move it back to make contact with the drop.
- 3- With steady movement of the hand, spread the drop of blood along the slide.
- 4- The film of blood should finish at least 1 cm before the end of the slide.

b) Staining: many staining procedures can be used according to the type of stain. The manufacturer instructions should be followed exactly. When using stain, the following procedures should be applied:

- 1- Fixing the film should be done with concentrated methanol for (2-3) minutes.
- 2- The specimen should be dipped in Eosin solution for 15 seconds before washing it in tap water.

- 3- After that, the specimen should be dipped in the stain. Wash it with tap water after that and allow it to dry.
- 4- Recording Red Blood Cells Morphology by Examination of Blood Film:
  - Scan area using -100X (oil immersion).
  - Observe 10 fields.
  - Red blood cells are observed for size, color, hemoglobin content or pallor, and shape. The discussion of the RBC morphology is in the following section.

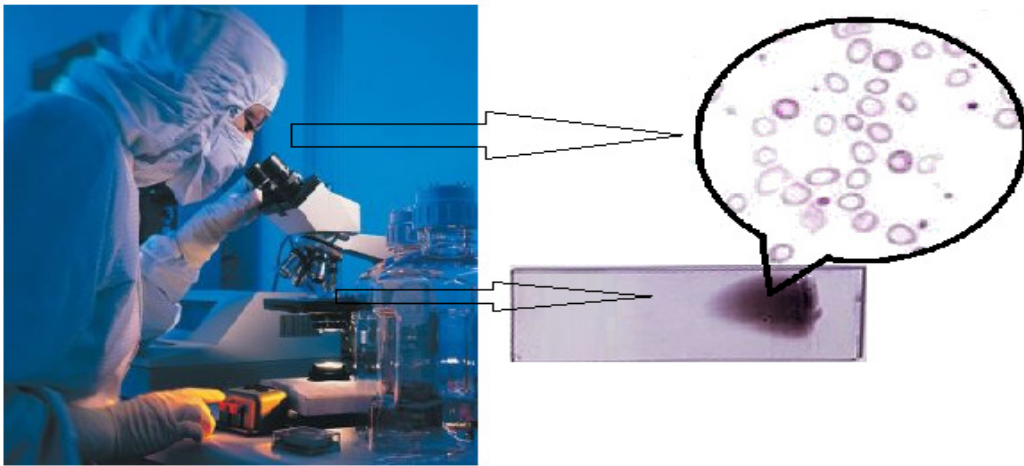


Figure (2.1) Blood smear reading by microscope.

### 2.1.3 Abnormal Morphology of RBCs

When assessing RBCs in the blood film five major features should be taken into consideration. These include: RBC size, color or hemoglobin content, shape, presence of intracellular inclusions, and RBC distribution in the smear.

Nevertheless, changes in other cell lines can also help in the diagnosis of the precise type of anemia. Before discussing the above features, it's worth knowing that in most individuals RBCs are 7.2  $\mu\text{m}$  in diameter(Turgeon, 2012), round biconcave in shape, normocytic, normochromic cells without intracellular inclusions, lying side by side in the blood smear. Note that red cell morphology must be scanned in a good counting area (Hoffbrand, Moss, 2011).

1- Red blood cells size: while examining the RBCs for their size, one can compare the size of RBCs to the size of nucleus of a small lymphocyte. RBCs that are larger or smaller than the size of the nucleus may be macrocytic or microcytic, respectively. Nonetheless, it's the value of MCV that make the precise decision of the RBC's size. Anisocytosis is present when the RBCs vary in size. (Turgeon, 2012)

The average size of an RBC is 7.2  $\mu\text{m}$  with a range of 6.8 to 7.5  $\mu\text{m}$ .

- Normocyte: normal size of RBC.
- Macrocyte: larger than the normal RBC (>8.2  $\mu\text{m}$ )
- Microcytic: smaller than the normal RBC, <7.2  $\mu\text{m}$ .

This is detected by elevated RDW in RBC indices. Anisocytosis is present in iron deficiency anemia with associated microcytosis and in megaloblastic anemia with associated macrocytosis. (Turgeon, 2012)

2- Color or hemoglobin content: after examining the size, Hemoglobin content should be checked. A normal erythrocyte has a pinkish-red color with a slightly lighter-colored center (central pallor) when stained with a blood stain, such as Wright, Leishman, Giemsa stain or other stains. Under normal conditions, when the color, central pallor, and hemoglobin content are proportional, the erythrocyte is referred to as normochromic. Cells with decreased hemoglobin content or increased central pallor are referred to as hypochromic.

3- Inclusions: the next to be examined is RBC inclusions. There are several inclusions that can be seen in erythrocytes: (Hoffbrand, Moss, 2011)

- Basophilic stippling: are tiny, blue granules, which are composed of RNA residues, diffusely distributed throughout the RBC. This is especially common in lead poisoning.
- Howell-jolly bodies: Is round dark- staining nuclear remnants. Their presence implies defective splenic function or a maturation defect.
- Reticulocyte: increasing red blood cells production is caused by younger enucleate red blood cells containing very small amount of RNA which are released from bone marrow respond to an anemia.
- Nucleated red blood cells: are abnormal red blood cells containing a nuclei that's normal situation can't be seen in blood smear, and when it's found that indicates severe hemolytic anemia.

4- Shape: red blood cells can take many shapes, Poikilocytosis is the general term for mature erythrocytes that have a shape other than the usual round, biconcave disk.

- Ovalocyte (Elliptocyte): an elongated oval cell, they are usually a result of a membrane defect. However, they can also be seen in iron deficiency anemia, megaloblastic anemia, thalassemia.
- Sickle cells: crescent shaped with usually one end pointed, they can vary in size but are usually smaller than the normal RBC. These occur due to decrease solubility and crystallization of hemoglobin. These cells characteristic of sickle Cell Anemia.
- Spherocyte: small red cells that lack the central pallor or biconcave disk, usually they are smaller than 6 micrometer and appear darker from the red cell background. Spherocytes can be seen in hereditary spherocytosis and various causes of hemolytic anemia.
- Stomatocyte: seen in hereditary membrane defect and alcoholism, it is red cell with a median streak pallor that resembles a mouth. The presence of stomatocytes suggests hepatic disease.
- Target cell: Red blood cell with a central darker area, bull's eye, which is surrounded by a clear ring and then an outer red ring. It can be observed in thalassemia or other hemoglobinopathies, and liver disease.
- Teardrop (dacrocyte): resembles a tear and. It is seen in hemolytic anemia and iron deficiency anemia, myelodysplastic syndrome and myelofibrosis.

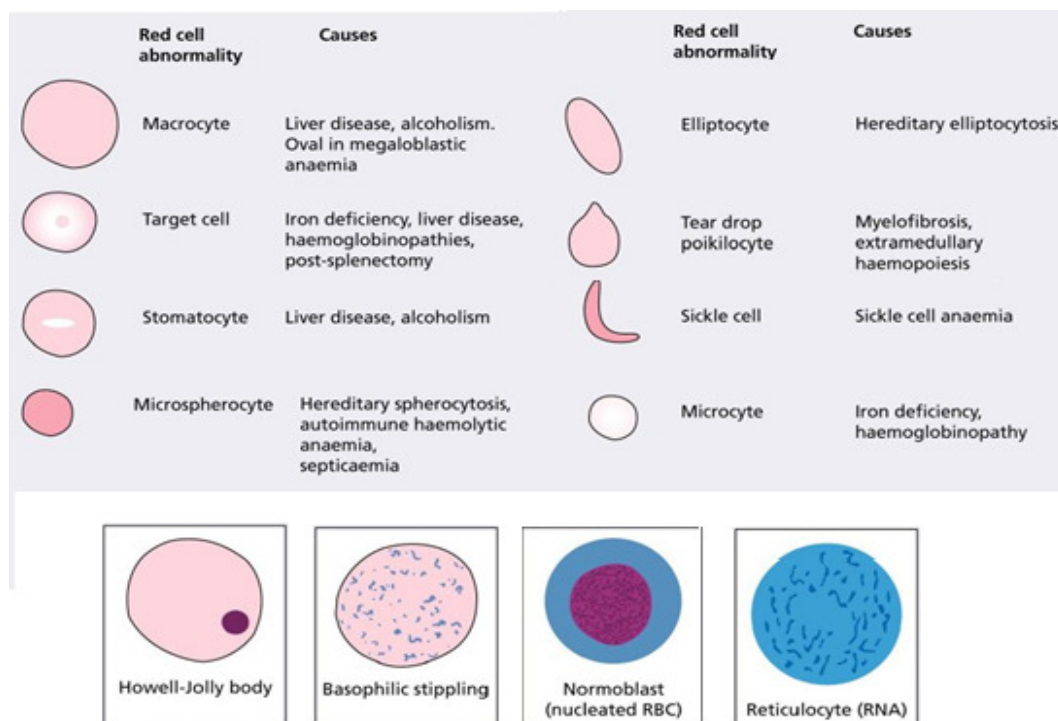


Figure (2.2) Morphology of Abnormal Red Blood Cells (Hoffbrand, Moss, 2011).

#### 2.1.4 Anemia Laboratory Diagnosis

The diagnosis of anemia is established when there is a decrease in hemoglobin and hematocrit below the normal values, as was mentioned earlier. Traditionally, physical examination and laboratory tests including peripheral smear examination are the critical steps in diagnosing anemia. (Fauci, et al., 2008)

### ➤ Iron Deficiency Anemia

Iron deficiency is a very common cause of anemia in the world, Iron deficiency without question is the most common nutritional deficiency. Frequently, persons die with this form of anemia but rarely from it. In a well-nourished person, iron deficiency anemia is a manifestation of an underlying disease process rather than a disease entity by itself.

Iron is a critical element in tissue metabolism; on the other hand, free iron is highly toxic acting as free radical generator. Knowing that, the body has developed mechanisms to handle iron while avoiding its toxicity; such as maintaining it hidden inside cells. The main function of iron is oxygen carriage as part of the hemoglobin contained within RBCs. Furthermore, iron is incorporated in mitochondrial enzymes used in cellular energy production.

Iron deficiency anemia is caused by negative iron balance, Iron balance is maintained by gastrointestinal absorption and epithelial shedding and bleeding as the sole physiologic mechanisms of iron intake and excretion respectively. When the body's demands or losses of iron overwhelm its ability to absorb iron from the diet, the anemia manifests.

Diagnostic criteria of iron deficiency anemia includes: low HB, low HCT, high platelet count, low MCV, high RDW , low serum iron, low serum ferritin, low transferrin saturation, high total iron binding capacity (TIBC) and changes on peripheral blood smear. Changes in the peripheral blood film in severe iron deficiency anemia, are microcytic and hypochromic RBCs and occasionally target cells. (Turgeon, 2012)



### ➤ Megaloblastic Anemia

Megaloblastic anemia is a group of disorders characterized by specific appearance of immature red blood cells in the bone marrow. This anemia is frequently due to folate or vitamin B12 deficiency. Moreover, abnormal metabolism of these vitamins, DNA synthetic defects and certain drugs can lead Megaloblastic anemia. (Fauci, et al., 2008)

Vitamin B12 (cobalamin) is a water-soluble vitamin composed of a cobalt atom incorporated in the center of a corrin ring. Humans cannot synthesize cobalamin; it's exclusively synthesized by microorganisms. The only source of cobalamin is food of animal origin; milk, eggs, meat. Human body contains about 2-3 mg, sufficient for 3-4 years if cobalamin supply were completely stopped. Daily requirements are 1-3 $\mu$ g, which equal daily losses. (Ciesla, 2007)

Cobalamin deficiency is usually caused by malabsorption or poor dietary intake. The latter can be seen in adult who are strict vegans. Vegans who omit animal products from their food like Hindus population in India are at great risk of B12 deficiency. Infant born to B12 deficient mothers can develop megaloblastic anemia usually in third to sixth month of age. Furthermore, malabsorption of cobalamin can occur in a variety of gastrointestinal diseases. Gastrectomy, pernicious anemia, celiac disease, iliac resection, tropical sprue, fish tapeworm infestation, and imerslund syndrome all can be causes of B12 malabsorption. The latter is the most common cause of megaloblastic anemia in infancy in the western world, Alcohol and drugs like metformin can decrease cobalamin absorption, however, rarely severe enough to cause megaloblastic anemia.

Patients with megaloblastic anemia have symptoms those of anemia, although many patients are detected incidentally. Anorexia, weight loss, Low grade fever, glossitis, jaundice, and skin hyperpigmentation may develop. Patient can have low platelet and leukocyte counts; predisposing them to bleeding and infections. (Turgeon, 2012)

The most affected tissue in the body is the bone marrow with its associated peripheral hematological findings. Macrocytosis with MCV  $>100\text{fl}$  accompanied by Poikilocytosis and anisocytosis are the most common features. Hypersegmented neutrophils-more than five nuclear lobes- are very characteristic finding. Upon examination the BM, hypercellularity with accumulation large primitive erythroblast is noticed. The diagnosis of megaloblastic anemia was achieved from studies of peripheral blood smear and BM among other tests recognizing B12 and folate body stores. (Ciesla, 2007)

#### ➤ Hemolytic Anemia

Hemolytic Anemia (HA) is a group of disorder characterized by decrease RBC survival in the face of insufficient BM compensatory response. HA can be inherited or acquired, acute or chronic, mild or severe, extra-vascular or intra-vascular. As mentioned before, a mature RBC is hemoglobin containing blood cell with 120 day-life span. Certain disorders can decrease this life span causing premature hemolysis and death of the cells. These factors can be internal to the RBC itself like enzymopathies or external to it like drugs and toxins.

---

### GENERAL FEATURES OF HEMOLYTIC DISORDERS

---

General examination :Jaundice, pallor

Other physical findings: Spleen may be enlarged; bossing of skull in severe congenital cases

Hemoglobin: From normal to severely reduced

MCV, MCH: Usually increased

Reticulocytes: Increased

Bilirubin: Increased (mostly unconjugated)

LDH: Increased (up to 10normal with intravascular hemolysis)

Haptoglobin: Reduced to absent

---

Table (2.1) General Features of Hemolytic Disorders. (Fauci, etal., 2008)

---

Clinical features of HA, as with other types of anemia, depend on whether the onset is acute or gradual. Besides that, HA exhibits characteristic features caused by either the hemolysis itself or the BM compensatory response. Jaundice, splenomegaly, and less often hepatomegaly most often point to a hemolytic process. Also, chronic hemolytic disorders may be associated with gall stones. In the serum, hemolysis causes increase in lactate dehydrogenase (LDH) and aspartate transaminase (AST). Haptoglobin is decrease.

Hemolysis that is predominantly extravascular causes increases in serum Bilirubin, urine Urobilinogen, and iron body stores. On the other hand, normal to slightly elevated serum Bilirubin and increase serum and urinary hemoglobin causing iron depletion are present in intravascular hemolysis. In response to the increased RBC destruction, erythroid hyperplasia is noted in the BM, and reticulocytosis in the peripheral blood.

On peripheral smear, macrocytosis (increased MCV) and polychromasia are noted indicating to increase reticulocytes. Tear drop cells, Spherocytes and nucleated RBCs may also be present. (Ciesla, 2007)

#### ➤ Hereditary Spherocytosis (HS)

Hereditary spherocytosis is a relatively common form of inherited hemolytic anemia. This condition is usually inherited in an autosomal dominant manner; although more severe autosomal recessive forms are also present. HS is caused by abnormality in the RBC's membrane- cytoskeleton complex. This ultimately result in spherical RBCs; providing that a sphere give the smallest surface area for a given volume. (Fauci, etal., 2008)

The clinical manifestations of HS vary widely from mild symptomatic hemolytic anemia to severe anemia that present in infancy. Jaundice, splenomegaly, and gallstones may be present. On laboratory tests, patients have low HB and increased MCHC, which is very specific to HS. On peripheral blood smear, this anemia is normocytic with presence of Spherocytes.

## ➤ Hemoglobinopathies

Hemoglobinopathies are disorders that affect hemoglobin production, structure, or function. Thalassemia is the most common genetic disorder in the world affecting nearly 200 million people globally.  $\alpha$  thalassemia is common in Africans and Asians, whereas  $\beta$  thalassemia occurs more in the Mediterranean and south-east Asian areas. Sickle cell anemia is the most common structural hemoglobinopathy. It is especially common in Africans, affecting about 8% of African Americans. Further discussion of thalassemia or sickle cell anemia follows. (Fauci, et al., 2008)

### ○ Thalassemia

The Thalassemia syndrome is caused by decreased synthesis of alpha or beta globin chains. This decrease is associated with relative excess of the other chain, which continues to be synthesized at a normal rate.  $\beta$ -thalassemia results from a defect in  $\beta$ -chain synthesis which results in accumulation of the unpaired  $\alpha$  chains.  $\alpha$ -chains are insoluble and cause inclusion bodies that are toxic to the cells. (Turgeon, 2012)

$\beta$ -thalassemia can be divided into:  $\beta^0$ -thalassemia with total absence of  $\beta$ -chains in a homozygous, and  $\beta^+$ -thalassemia with reduced  $\beta$ -chains in a homozygous. Clinically however, it can be classified into  $\beta$ -thalassemia major (homozygous) with severe hemolysis that is transfusion dependent,  $\beta$ -thalassemia intermedia has milder anemia is usually transfusion-independent, and lastly,  $\beta$ -thalassemia minor or trait that is asymptomatic or has mild symptoms. (Fauci, et al., 2008)

Patients with thalassemia syndromes may have hepatomegaly, splenomegaly, and lymphadenopathy due to extramedullary erythropoiesis. The latter also causes skeletal deformities, growth retardation, and secondary iron overload even in the absence of transfusion. Because of decreased hemoglobin synthesis, peripheral blood will show hypochromic microcytosis. RBCs tend to have high surface area to volume ratio that results in target cells. Reticulocytosis, poikilocytosis, and anisocytosis are also present. Presence of premature forms of RBCs in the peripheral blood indicates erythroid hyperplasia.

- Sickle Cell Anemia

Sickle cell anemia is caused by mutation in the gene of  $\beta$  chain in chromosome 11. This mutation give rise to a protein that reversibly loses its solubility and crystallizes when deoxygenated. Because hemoglobin has a great concentration in RBCs, this abnormal hemoglobin gives RBCs a characteristic sickle shape. Dehydration, abrupt changes in temperature, infection, excessive exercise, anxiety and dyes can precipitate this sickling phenomenon. (Fauci, etal., 2008)

Pain crises are the most common clinical manifestation of sickle cell anemia. It occurs when the sickle RBCs, that have less deformability than normal cells, get stuck in small vessels occluding them. Stroke, pulmonary infarction, renal failure, hematuria due to papillary necrosis, osteomyelitis due to salmonella, dactylitis, and priapism in males can all occur in sickle cell anemia.

However, this disease has great clinical heterogeneity that some patients may remain asymptomatic throughout life. Other crises that can affect these patients are sequestration crisis and aplastic crisis.

The laboratory tests show hemoglobin that is usually 6-9 grams/dl. Granulocytosis is common. Moreover, findings of extravascular hemolysis mentioned earlier are also presented. The Blood film shows crescent, elongated boat-like sickle cells. Anisocytosis, poikilocytosis, nucleated RBCs and target cells may also be seen. Also the diagnosis of sickle cell anemia is done by hemoglobin electrophoresis and sickling tests.

#### ➤ Aplastic anaemia

It is defined as pancytopenia with decrease in all three formed elements of the blood. It is caused by bone marrow failure. Aplastic anemia affects persons of all ages with the peak being in teens. Both sexes are affected equally. While most cases are idiopathic, a variety of causes can lead to aplastic anemia such as drugs, infections, radiation, inflammatory, and malignant conditions. (Fauci, etal., 2008)

Aplastic anemia appears with bleeding as the most common early symptom. Symptoms of anemia such as fatigue, shortness of breath, palpitations are also frequent. Infection is an atypical first symptom in aplastic anemia. However, patients can also look well despite their low blood counts. Petechiae, ecchymoses, pallor may be seen. (Fauci, etal., 2008)

The smear shows large RBCs and a small number of platelets and Granulocytes, (MCV) is usually increased, Reticulocytes are absent or reduced, Anemia is normochromic, normocytic or macrocytic, Tear-drop red cells may also be noticed in the blood smear. The diagnosis of aplastic anemia depends on the presence of pancytopenia coupled with fatty bone marrow on BM biopsy. (Turgeon, 2012)

### **2.1.5 Summary**

Anemia is a major health problem that affects millions of people worldwide. Significant burden of morbidity and mortality is caused by the various causes of anemia. Nevertheless, anemia itself is just a manifestation of other diseases that may be either benign or malignant.

There are numerous types of anemia converge and diverge regarding their prevalence, epidemiology, etiology, pathogenesis and management. In the usual cases, anemia is an incidental finding. In other cases, it may present dramatically with severe excruciating pain like pain crisis in sickle cell anemia.

All in all, the importance dealing with anemia stems from that it is a readily diagnosable and treatable condition. Diagnostic studies range from simple as blood count to invasive as bone marrow biopsy. In spite of the presence of so many blood tests, examination of the peripheral blood smears is one of the most informative exercises a physician performs. The examination of blood smears by a physician who knows the patient past history, nutritional history, social and family history is with great value.



## **2.2 Image Processing Techniques**

Image processing is one of the branches of computer science, its task is focused on performing certain processing on images in order to enhance them or extract certain types of information, according to already predetermined criteria. Traditional image processing techniques consisted of six sequential steps, which are: image acquisition, pre-processing, segmentation, feature extraction, classification, and finally image understanding. Image processing techniques have many applications; however, in this work the researcher used that in biomedical image processing to develop a system that helps improving anemia diagnosis.

Developing a computer-based information system using image processing techniques that need to use well-supported programming environment which has wide range of functions in digital image processing, so in this work, MATLAB version 7.10.0.499 (R2010a) (programming environment for algorithm development) has been used to develop a computer-based information system with the associated user-friendly interface suitable for executing the requested activities.

MATLAB is the most widely used engineering program in several areas with regard to engineering, calculations and simulation, image processing, and other functions as this program is used for academic purposes, especially for scientific research purposes. MATLAB covers many industries (such as aerospace and defense, automotive, biotechnology treatment, medicines, and medical industries, telecommunications).

MATLAB environment is not a single program but a ready-made software package which contains a set of tools and facilities that carry out the analysis and representation of data with which programmers deal. MATLAB is produced by Inc. (Mathurk. Enk) the name was derived from (Matrix laboratory), because the infrastructure in All MATLAB orders is the matrix.

There are many functions in MATLAB which help in developing image processing systems such as (imread, rgb2gray, imadjust, im2bw, bwareaopen, bwboundaries, and impixel).see table (2.2)

Function name	Description
Imread	Read image from graphics file
rgb2gray	Convert RGB image or color map to grayscale
Imadjust	Adjust image intensity values or color map
Im2bw	Convert image to binary image, based on threshold
Bwareaopen	Remove small objects from binary image
Bwboundaries	Trace region boundaries in binary image
Impixle	Pixel color values
Regionporps	Measure properties of image regions

Table (2.2) Some of MATLAB Functions. (Natick, 2010)

### ➤ **(imread) function**

The syntax: `I = imread(filename, fmt)`

Grayscale or color images are read using the function `imread`. The function utilizes the specified file by its string file name. Unless when the file is already in a folder in MATLAB, the full pathname should be used. The return value of the function is an array containing the image data, in case of gray scale images the array is an M-by-N and for true color images the array is M-by-N-by-3. Once more, the array in color images using CMYK color space contained in TIFF files is M-by-N-by-4.

- Example

```
I= imread('image1.jpg');
```

### ➤ **(rgb2gray) function**

The syntax: `I = rgb2gray(RGB)`

RGB color images are converted to gray scale intensity images by the function (`rgb2gray`). The function achieves that task by preserving the original image illumination while removing the color and saturation information.

### - **Algorithm**

Natick,( 2010) `rgb2gray` converts RGB values to grayscale values by forming a weighted sum of the R, G, and B components:  $(0.2989 * R + 0.5870 * G + 0.1140 * B)$

- Example: convert an RGB image to a grayscale image.

```
I = imread('board.tif'); J = rgb2gray(I);
```

➤ **(imadjust) function**

The syntax: `D = imadjust(I)`

The function enhances the contrast of the grayscale image by changing the intensity values of the image to new values. The resulted image has 1% of the data saturated at low and high intensities value.

- Example: adjust a low-contrast grayscale image.

```
I = imread('image1.jpg');
```

```
J = imadjust(I);
```

➤ **(Im2bw) function**

The syntax: `BW = im2bw(I, level)`

This function converts the grayscale image to a binary image. All pixels in the input image are replaced by the value 0 unless the pixels' illumination is above certain threshold value in which case it is replaced by value one. Value 0 and 1 represent black and white colors respectively. The threshold value should be in the range [0, 1]. If you do not specify the threshold value, the function uses the value 0.5, which is middle between black and white.

In case of using RGB images instead of grayscale images, the function converts it into grayscale format then into binary image as described above.

➤ **(bwareaopen) function**

The syntax: `BW2 = bwareaopen(BW, P, conn)`

The function achieves the task of area opening on binary images. This comprises removing all objects with pixel value less than P pixels producing another binary image. The default connectivity is 8 and 26 for two and three dimensions respectively.

- Example: Remove all objects in the image poss.png containing fewer than 30 pixels:

```
BO = imread('poss.png');
BO2 = bwareaopen(BW, 30);
```

➤ **(Bwboundaries) function**

The syntax: `B = bwboundaries(BW,conn,options)`

This function outlines the boundaries of objects in addition to boundaries of smaller objects, holes, contained within the original objects. The used image must be a binary image, where the background and the image are represented by zero pixels and non-zero pixels respectively. The outcome constitutes the number of objects and holes in one cell-array. The function `B=bwboundaries (image, conn)` defines the used connectivity when tracing the boundaries of objects and holes. (Gonalez, Woods, & Eddins 2004)

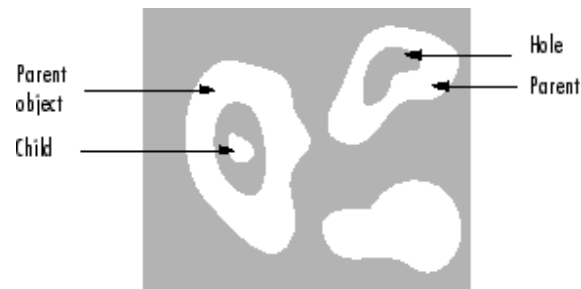


Figure (2.3) Boundaries of Objects and the Holes (Natick, 2010)

➤ **(impixel) function**

The syntax: `P = impixel (RGB)`

This function gives the RGB color value back to certain pixels. These pixels can be specified differently according to the specific requirements.

- Example: `c = [14 152 104]; r = [108 112 170]; p1 = impixel(RGB,X1,Y1)`

➤ **(regionprops) function**

The syntax: `S= regionprops (BW, properties)`

The function measures a group of properties for each connected component (object) in the binary image. The image can have any dimension as it is a logical array. The following is short description of the proprieties that image components may have:

**Area:** is represented by the number of pixels in the region. (The value given by `bwarea` may exhibit slight differences as the patterns of pixels are weighted differently.)

**BoundingBox:** The minimum rectangle enclosing the region, a 1-by-Q \*2 vector, where Q is the number of image dimensions: `ndims(L)`, `ndims(BW)`, or `numel(CC.ImageSize)`. `BoundingBox` is [`ul_corner` width], where:

**Centroid:** 1-by-Q vector that specifies the center of mass of the region. It consists of two coordinates the x (horizontal) coordinate and the y (vertical) coordinate. All other elements of `Centroid` are in order of dimension.

**MajorAxisLength:** represents the length (in pixels) of the axis that connects the two farthest points of the ellipse that has the same normalized second central moments as the region. This property is supported only for 2-D input label matrices.

**MinorAxisLength:** represents the length (in pixels) of the axis that connects the two nearest points of the ellipse that has the same normalized second central moments as the region. This property is supported only for 2-D input label matrices.

## 2.3 Literature Review

In this section reviews of previous similar works are made. Those efforts are related to identifying various diseases using different automated techniques and classification processes.

Bikhet, Darwish, Tolba & Shaheen (2000) presented a set of pre-processing and segmentation algorithms that were able to recognize and classify different categories of normal white blood cells based on morphological characteristics of their outer contour and nuclei. This was achieved by image pre-processing in order to improve the image and remove impurities. Afterwards, cells were divided from the background. Finally features were extracted to categorize each cell into one of five classes of WBCs. The main advantage of that algorithm is the low computational complexity required. However, there were some problems in the areas of overlapping and touching cells.

Sinha & Ramakrishnan (2002) presented a method for segmentation of WBCs from color images of blood smears in the framework of statistical modeling. This approach resulted in locating each WBC and identifying the region corresponding to the nucleus and cytoplasm in a given blood smear, even when the WBC was multinucleated. The suggested algorithm required no user-interaction or parameter tuning.

Ahadidi, ZU'bi & Suleiman (2007) application was based on MATLAB software to detect cancer in images taken from mammograms of the breast. They found that segmentation by threshold was the fastest, while the output images were better by using edge-based and watershed processing. The conclusion is that edge-based processing was one of the earliest segmentation approaches and is still very important.

Alhadidi & Fakhouri (2008) presented improved algorithm that achieved an automated way of analyzing images taken from intestinal villi. It counted the number of blue and red stained cells that contain iron in each villus alone. It also calculated the percentages of blue and red cells in the image .



Hamghalam, Motameni, & Kelishomi, (2009) this paper presented a leukocyte segmentation method using three major categories: boundary-based, region-based and threshold-based that were used to detect the precise boundaries of nuclei in the image. The active contour was employed to find the precise boundaries of the cytoplasm. They were able to segment nuclei independently of the intensity differences in Giemsa-stained blood smears. Using this method, nuclei were segmented and detected. The elimination of the nucleus and the improved speed of convergence in thresholded image; cause the localization of the initial snack everywhere inside the body of the leukocyte.

Hirimutugoda & Wijayarathna (2010) studied the possibility of fast and accurate automated diagnosis of red blood cell disorders. They described a method to detect malarial parasites and thalassemia in blood sample images. Their paper discussed artificial neural network with image processing techniques using the morphological features of red blood cells to automate the evaluation of the blood disorders.

Sharif, Miswan, Ngadi, Salam & Abdul Jamil (2012) presented an approach for RBC segmentation. The main idea was the use of masking and morphologic operation function to remove unneeded objects. It used the technique from mixture of pixel-based, region-based and morphological segmentation to improve image segmentation accuracy.

## Chapter Three

### System Model Design and Implementation

#### 3.1 System Model Design

The system composed of many subsystem and components that work together to achieve the goals, the system implementation must be based on a true and correct design, that is by intelligent design of subsystems with their components and the links between them to create the integrated system and show the relationships between it. See figure (3.1)

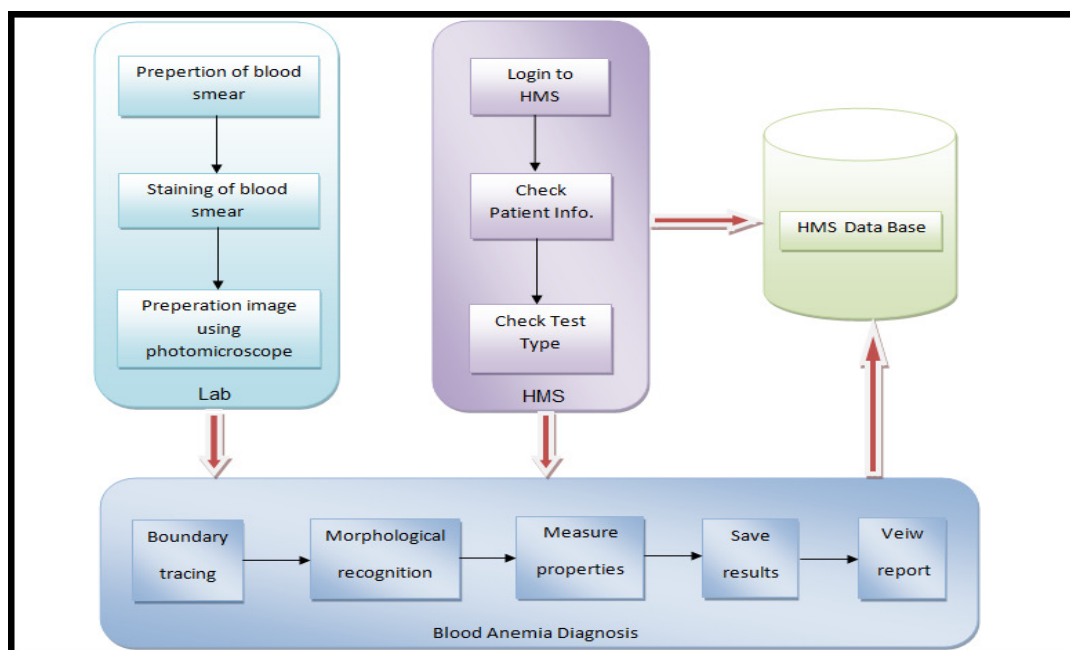


Figure (3.1) Subsystem and Components Design.

The system is divided into three main sub systems as shown below:

1. Lab: it's the environment in which the sample is taken, sample preparation, and staining to be ready for examination.
  - a. Preparation of blood smear: it is process of blood sample taking and putting it on the smear.
  - b. Staining of blood smear: it is the process of staining blood smear by one of stain type such as Wright, Leishman, Giemsa stain or other stains.
  - c. Preparation image using photomicroscope: process of taking image of blood smear under microscope that supplied with a camera.
2. Hospital Management System (HMS):
  - a. Login to HMS: access to hospital management system.
  - b. Check patient information: The patient check-in process includes verifying and updating information in the HMS system.
  - c. Check test type: check the case, which is the query if the particular patient has any cases.
3. Blood Anemia Diagnosis System :
  - a. Boundary tracing: to determent each cells as area and labeling it.
  - b. Morphological recognition: extraction all morphological feature of each cell.
  - c. Measure properties: A measure of sets of prosperities, the measurable sets for each element used to determine the type and properties of each cell and properties of it.
  - d. Save result: save all the result in mane storage or server or secondary storage as needed.
  - e. View report: display report of outcomes and results of the analysis on screen or hard copy.

### 3.1.1 Process Operations Representation

The type of diagrams that represents a process operations by boxes and arrows, they are implied by the sequencing of operations. See figure (3.2)

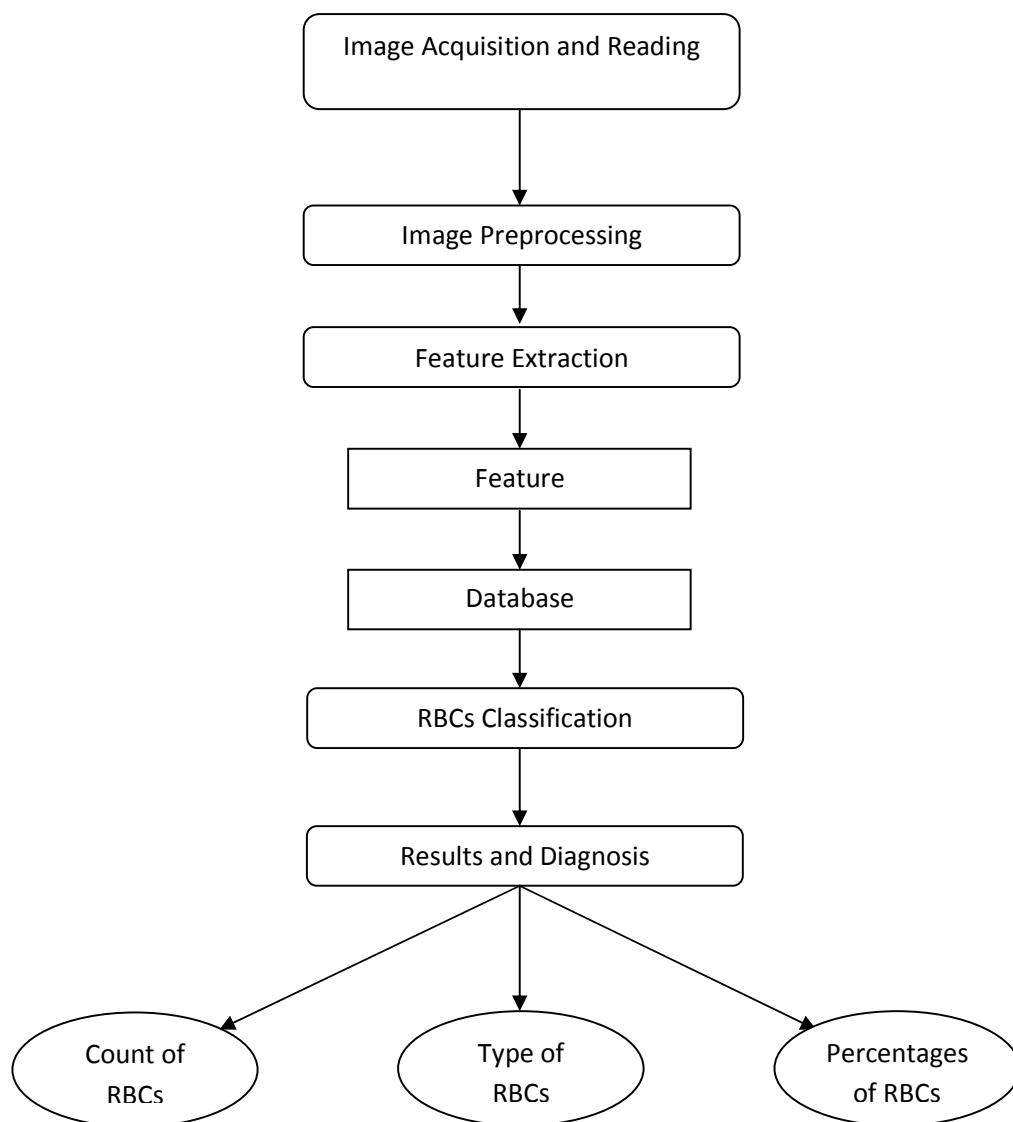


Figure (3.2) Process Operations Flowchart.

### 3.1.2 Graphical Representation of Processing

Data flow diagram (DFD) is a graphical representation showing the processing steps of data passing through certain information system. It shows the types of information needed as inputs and those that resulted as outputs. It also shows data flow direction and where should it be stored. However, neither the timing of the processing nor whether the processes will operate in sequence or in parallel would show.( Bruza, &Van der Weide, 1993).

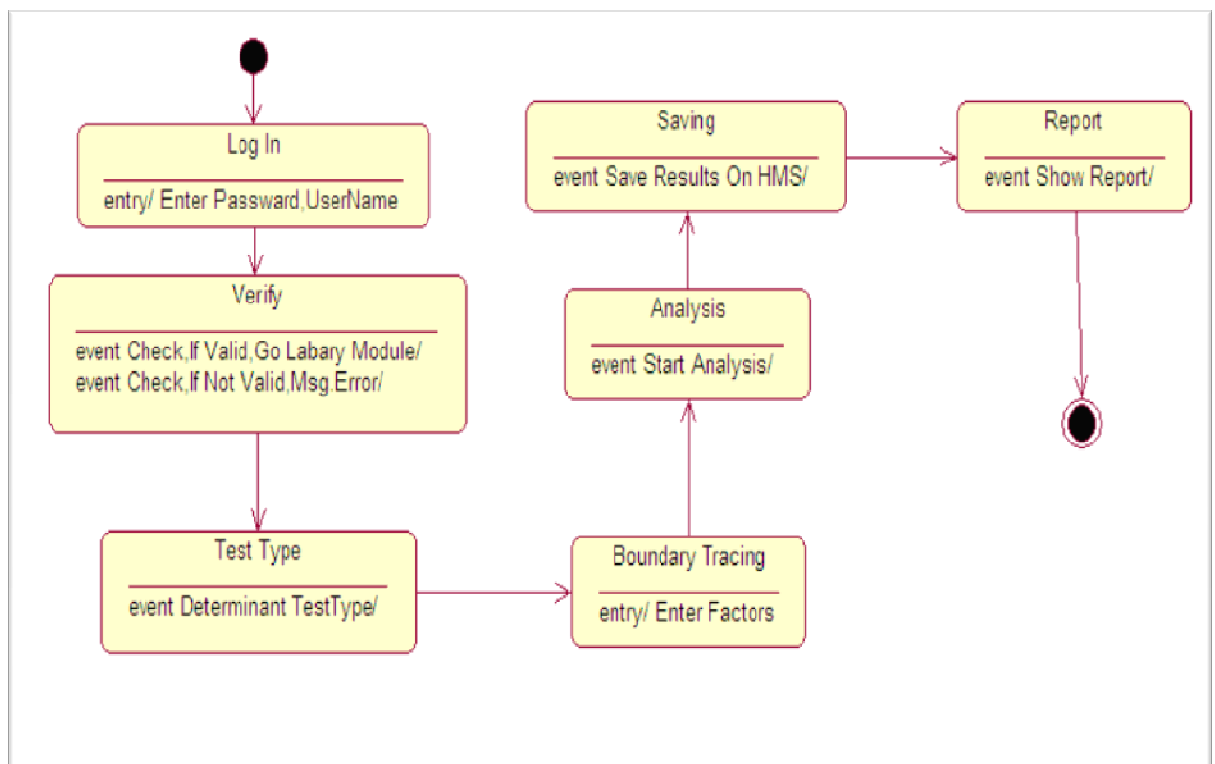


Figure (3.3) Graphical Representation of Processing (Flow Diagram).

### 3.1.3 User's Interaction with the System Representation

In any system, it must accept the application of a lot of different scenarios to be used, for example, in some of our transactions realized using all system components through work with each other, and others can be achieved using a single component, and this reflects the flexibility to use the system to achieve the various scenarios that applied to the system. Figure (3.3) shows some cases that can be applied to this system and how to use.

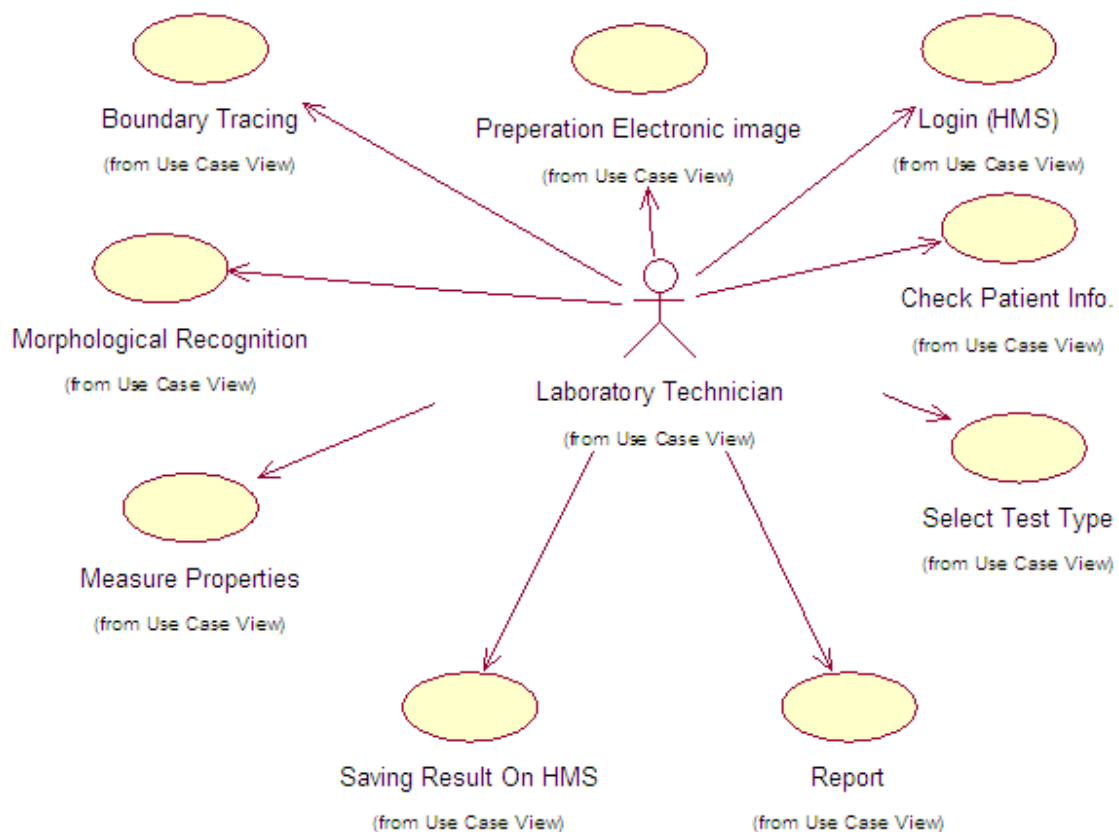


Figure (3.4) User's Interaction with the System Representation (Use Case) .

### 3.1.3 Scenarios: Sequence Diagram and Collaboration Diagram

In this section, the researcher shows main scenario and the steps order when using then scenario Diagram, at show in Figure (3.4).

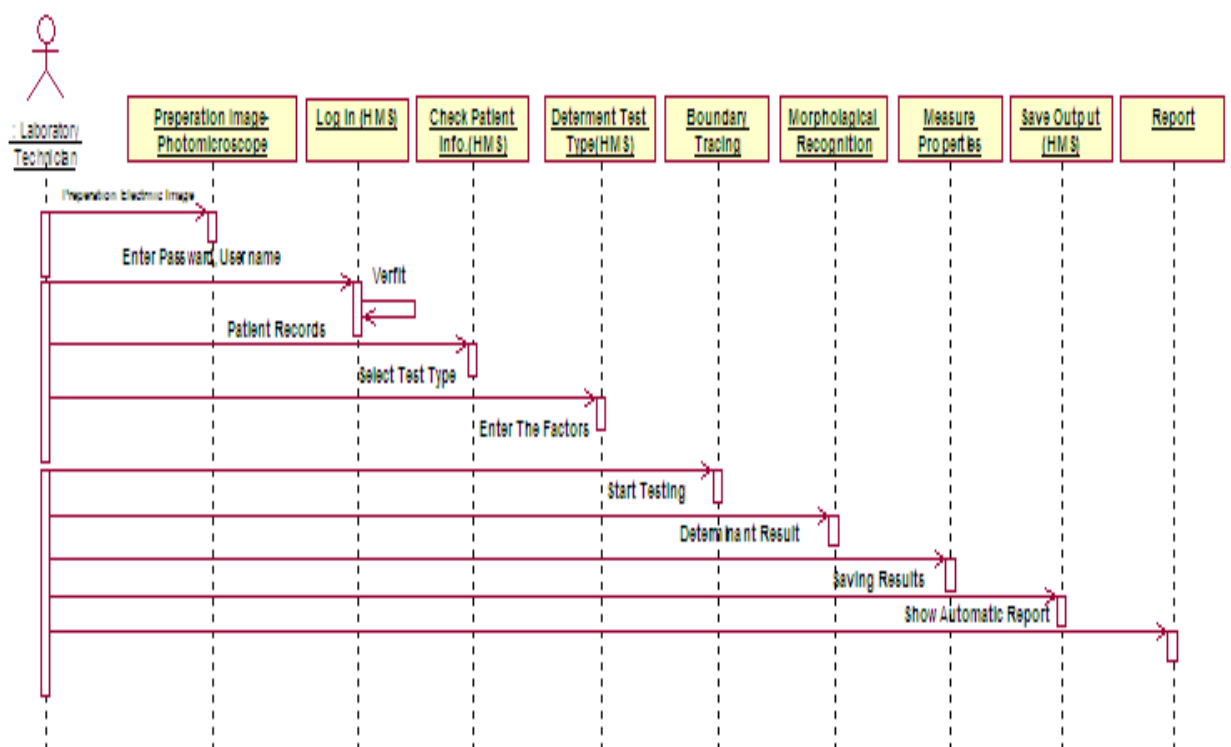


Figure (3.5) Sequence of Main Scenario

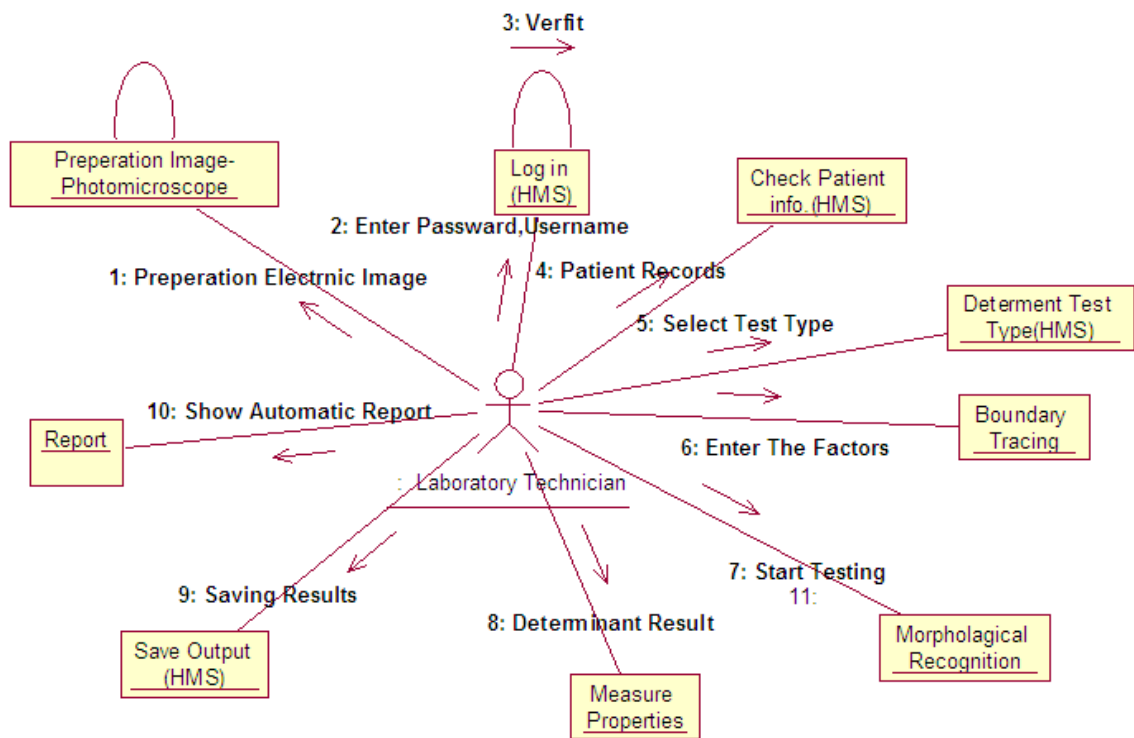


Figure (3.6) Collaboration of Main Scenario.

### 3.2 System Application Phases

In this thesis a computer-based information system has been developed and used to enhance blood anemia diagnosis has been developed, the system is divided into five main parts in succession. The main strategic five phases (image reading, preprocessing, features extraction, classification, results and diagnosis) that the blood smear image will pass through in the recognition process.



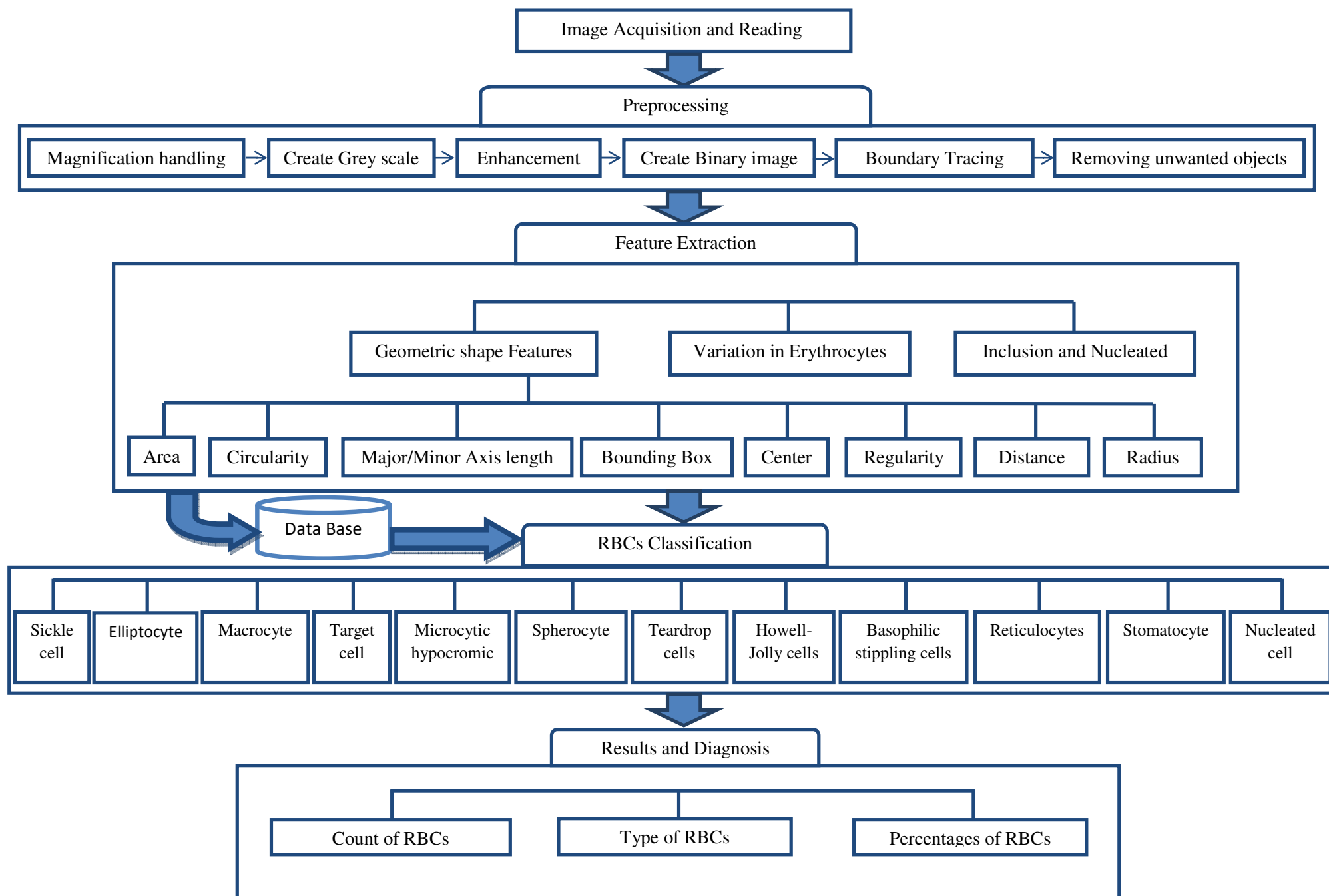


Figure (3.7) System Application Phases

After the arrival of RGB-image to the computer that contains the analysis system, the process analyzing a blood sample can be started, but you must first enter factors affecting the process of analysis, in order to give more accurate result in the blood analysis, then the classification process can begin based on the analytical module which contain the classification conditions and the factors.

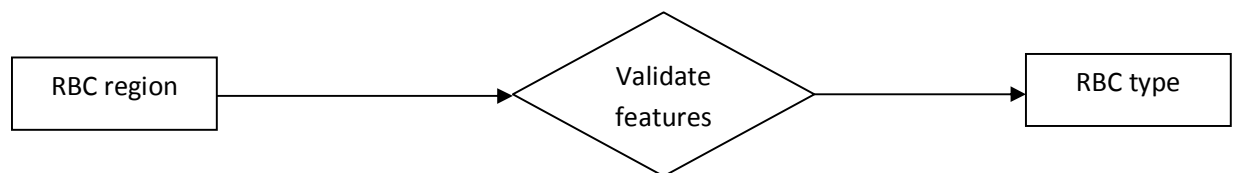


Figure (3.8) RBCs Classification.

Red blood cells will be classified based on features validation, which will be extracted after edge detection, in this system there are sets of features extracted in thesis system that is (area, major/minor axis length, ratio, circularity, bounding box, center, variation in erythrocyte color, inclusion and nucleated). The next figure shows each cell with features.

<b>Microcytic &amp; hypochromic cell</b> <ul style="list-style-type: none"> <li>- Cell area <math>&lt; 0.85 * \text{minimum area of normal RBCs}</math></li> <li>- Ratio of cell <math>&lt; 1.2</math></li> <li>- Green layer value <math>&gt; 140</math></li> </ul>	<b>spherocytes</b> <ul style="list-style-type: none"> <li>- Cell area <math>&lt; 0.85 * \text{minimum area of normal RBCs}</math></li> <li>- Cell Ratio <math>&lt; 1.2</math></li> <li>Green layer value <math>&lt; 140</math> &amp; Red layer value <math>&gt; 140</math></li> </ul>	<b>Macrocytes</b> <ul style="list-style-type: none"> <li>- Cell area <math>&gt; \text{Maximum area of normal RBCs}</math></li> <li>- Cell Ratio <math>&lt; 1.2</math></li> <li>- Green layer value between (100-200)</li> </ul>
<b>Basophilic stippling cells</b> <ul style="list-style-type: none"> <li>- Cell area <math>&lt; \text{Maximum area of normal RBCs}</math></li> <li>- Cell ratio <math>&lt; 1.5</math></li> <li>- Inclusion <math>&gt; (\text{magnification} / 125)</math> and <math>&lt; (3 * (\text{magnification} / 125))</math></li> <li>- Blue layer value for inclusion <math>&gt; 70</math></li> <li>- Number of inclusion <math>&gt; 9</math></li> </ul>	<b>Howell-Jolly cells</b> <ul style="list-style-type: none"> <li>- Cell area <math>&lt; \text{Maximum area of normal RBCs}</math></li> <li>- Cell ratio <math>&lt; 1.5</math></li> <li>- Inclusion area <math>&gt; (\text{magnification} / 125)</math> and <math>&lt; (3 * (\text{magnification} / 125))</math></li> <li>- Blue layer value for inclusion <math>&gt; 70</math></li> <li>- Number of inclusion <math>&lt; 3</math></li> </ul>	<b>Reticulocytes cells</b> <ul style="list-style-type: none"> <li>- Cell area <math>&lt; \text{Maximum area of normal RBCs}</math></li> <li>- Cell ratio <math>&lt; 1.5</math></li> <li>- Inclusion area <math>&gt; (\text{magnification} / 125)</math> and <math>&lt; (3 * (\text{magnification} / 125))</math></li> <li>- Blue layer value for inclusion <math>&gt; 70</math></li> <li>- Number of inclusion between (3-9)</li> </ul>
<b>Sickle cells</b> <ul style="list-style-type: none"> <li>- Cell region area <math>&gt; \text{maximum area of normal RBCs}</math> and <math>&lt; \text{minimum area of normal RBCs}</math></li> <li>- Green layer value for center between 100-200</li> <li>- Irregular shape.</li> </ul>	<b>Tear drop cells</b> <ul style="list-style-type: none"> <li>- Cell area <math>&lt; 1.7 * \text{maximum area of normal RBCs}</math> and <math>&gt; 1.7 * \text{minimum area of normal RBCs}</math></li> <li>- Ratio is between (1.2 – 2.2)</li> <li>- Irregular shape.</li> </ul>	<b>Elliptocytes</b> <ul style="list-style-type: none"> <li>- Cell area <math>&lt; 1.3 * \text{maximum area of normal RBCs}</math> and <math>&gt; 1.3 * \text{minimum area of normal RBCs}</math></li> <li>- Ratio for cell <math>&gt; 1.75</math></li> <li>- Green layer value <math>&gt; 200</math></li> <li>- Regular shape.</li> </ul>
<b>Target cells</b> <ul style="list-style-type: none"> <li>- Cell area <math>&gt; \text{maximum area of normal RBCs}</math> and hole area <math>&gt; 30 \text{ pixel}</math></li> <li>- Cell Ratio <math>&lt; 1.2</math></li> <li>- Hole ratio <math>&lt; 1.6</math></li> <li>- Make sure that the hole inside the cell</li> <li>- Green layer value for center or center <math>\pm</math> on (x and y axis) is between (100 – 200)</li> </ul>	<b>Stomatocytes</b> <ul style="list-style-type: none"> <li>- Hole area <math>&gt; 50</math> and cell area <math>&lt; 2 * \text{double of maximum area for normal}</math></li> <li>- Cell ratio <math>&gt; 1.5</math></li> <li>- Make sure that the hole inside the cell.</li> </ul>	<b>Nucleated cells</b> <ul style="list-style-type: none"> <li>- Nucleated cell area <math>&lt; 0.7 * \text{maximum area of normal RBCs}</math> &amp; area <math>&lt; 1.5 * (\text{cell area} - \text{nucleated})</math></li> <li>- Area and nucleated ratio <math>&gt; 1.5</math></li> <li>- make sure hole inside the cell.</li> </ul>

Figure (3.9) Red Blood Cells Classification Conditions.

The blood smear image goes through many steps to detect whether the red blood cells are normal or abnormal and to determine the type of each one, these results will lead to finding anemia disease and its type.

The approach could be viewed as five a processing phase. First image reading, then the image is preprocessed to enhance it and remove noise, then red blood cells are separated from the background then features are extracted to identify and classify each red blood cell into one of 12 type of RBC's, finally calculating the count of each classified red blood cells that will lead to diagnosis of anemia in the following is a brief explanation of each phase.

### **3.2.1 Image Acquisition and Read Image**

In this phase the image will be read from the file specified by the string (file name) and format, and then store it as matrix. Knowing that the Photomicroscope is resource of the tested image of blood smear, the images taken maybe differ in the magnification time and maybe stored in many format, but the application is able to handle by using these calculating methods.

The Function:

```
X = imread(filename,format);
```

The IMREAD function in the MATLAB environment read the image in any supported format (bmp, hdf, jpeg, pcx, png, tiff, xwd) from any graphical file either gray scale or

color image but this work will focus on the RGB-image (color image) because the gradient variation helps distinguishing between cells types. (Natick, 2010)

Dealing with different formats has an effect on images and on its processing as there are many kinds of formats that use data compression to reduce the file size and save storage space. As is the case when using the JPG format that compresses the image using a loss algorithm (Lucy Compression), and thus the greater the reduction of image quality or detail that cannot be restored. By contrast, when we use the PNG format which compresses data without loss where it does not lose any information when the file is saved. In this work study as samples of both types were used but no differences were observed clearly.

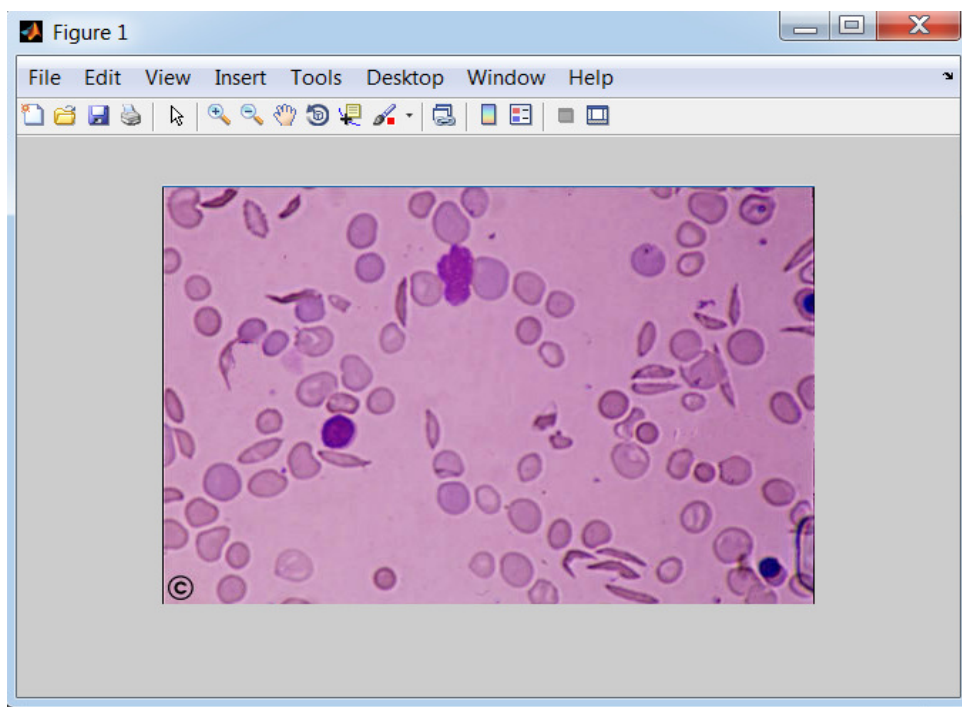


Figure (3.10) RGB-Image of the Blood Smear

### 3.2.2 Image Preprocessing

A set of processes is used in data preparation and filtering to remove the noise. An intelligent implementation is used to make it ready for later analysis later with the aim to automate cognition of the image and its content without human help. The techniques used at this phase are different according to the nature of information needed to be extracted from the image.

A set of sequential processes (handling magnification , create gray scale image, enhancement image using imadjust, create binary image, boundary tracing, removing small objects, removing intersected cells, removing cells at boundary)has been applied to the original image after image acquisition and reading as a digital image, which will be explained as shown below:

#### 3.2.2.1 Handling Image Magnification

The image taken after enlargement using photomicroscope, so the amount of magnification should be inserted into the system, then the method will compute the real area of objects upon the amount of magnification. There are many magnification equations such as:

##### ❖ Magnification value /10

This equation assimilate very small objects, the equation used as a variable to be dynamic with magnification , result of this equation has been used as compare factor for area, in this application it will be used in one of the steps for recognizing small object.

Example:

Magnification value = 2000

The small objects area = 100 pixels

❖ Magnification value /13

This assimilation equation has been used to make a comparison with the (height and width) of bounding box to be sure that this area assimilate the true cell.

Example:

Magnification = 2000

The height or width = 153.85 pixels

This result will be used as a factor of recognizing intersected cells.

❖ Magnification value \* 0.45

This equation assimilates minimum area of RBCs after magnification, the equation used as a variable to be dynamic with magnification, result of this equation has been used as compare factor for area, in this application it will be used in one of the steps for recognizing small cells.

Example:

Magnification = 2000s

Minimum area of RBCs after magnification = 900 pixels.

❖ Magnification value \* 0.85

This equation assimilates maximum area of RBCs after magnification, the equation used as a variable to be dynamic with magnification, result of this equation has been used as compare factor for area, in this application it will be used in one of the steps for recognizing large cells.

Example:

$$\text{Magnification} = 2000$$

$$\text{Maximum area of RBCs after magnification} = 1700 \text{ pixels}$$

❖ Magnification value/400

This equation assimilate the radius of normal cells, value used as a variable to be dynamic with magnification , it has been used to recognize if this cell is regular or not, in this application it will be used in one of the steps for recognizing sickle cells.

❖ Magnification value /700

This equation assimilates the radius of normal cells, value used as a variable to be dynamic with magnification, it has been used to recognize if this cell is regular or not. In this equation the denominator has been changed to be appropriate with other cases; in recognizing of Elliptocytes and Teardrop.

❖ Magnification value / 125

This equation assimilates area of inclusions, in recognizing Reticulocytes, Howell-Jolly body and Basophilic stippling.



### 3.2.2.2 Creating Gray Scale Image

The image of blood smear had been taken by photomicroscope which is colored, but in some of the coming next phases for the system is handled with 2-dimention images (that only includes gray scale), so the image should be converted to gray scale.

The function:

Grayscale-image=rgb2gray (image-name);

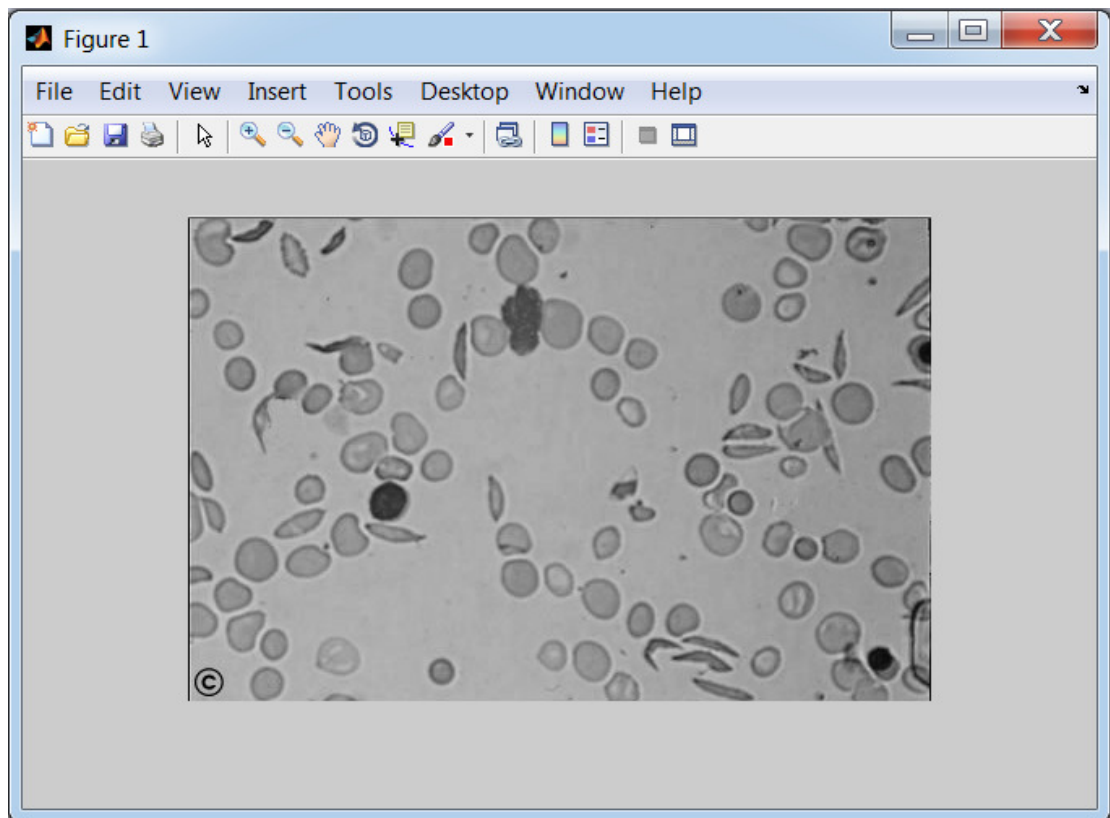


Figure (3.11) Gray Scale Image after Using (rgb2gray) Function.

### 3.2.2.3 Image Enhancement Using IMADJUST

It's a set of methods that help us enhancing images to easily localizing regions from the study image, there are many methods for image enhancement, but the method used for one application is not necessarily suitable for another application. It may be suitable to enhance x-ray image but not for images sent by space probe, so the chosen method for image enhancement should select the suitable way. In this work the imadjust has been used to increase the contrast of the image and to Enhance color difference between background and objects that will be useful in extracting the objects boundary.

The function:

```
imadjust-image=imadjust(image-name);
```

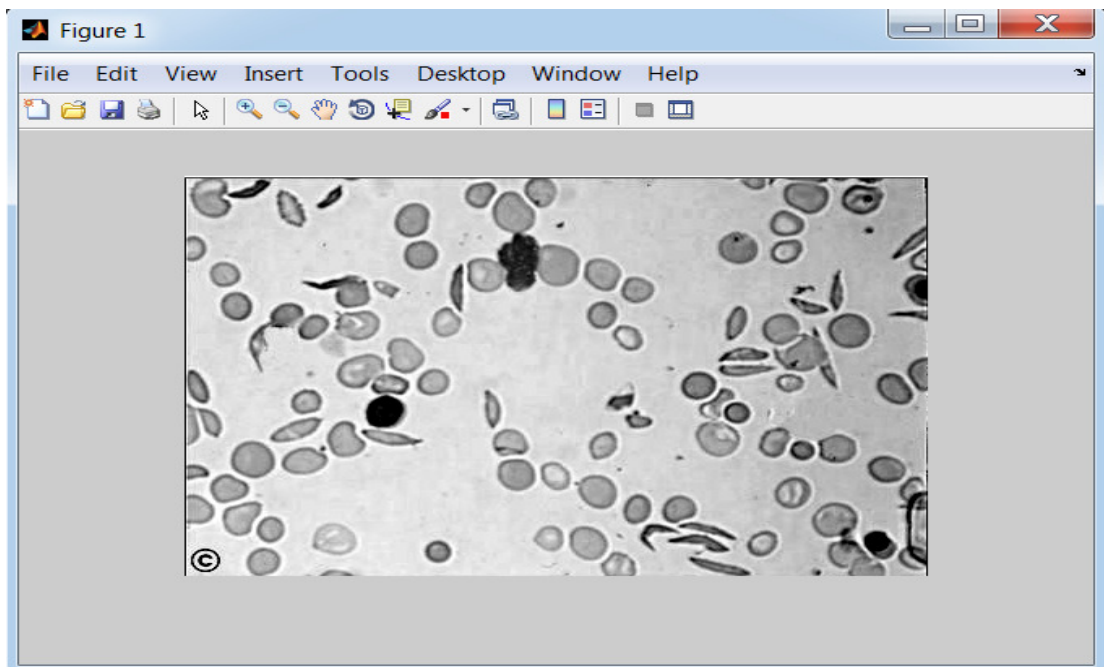


Figure (3.12) shows Image Enhancement using (imadjust) Function.

### 3.2.2.4 Creating Binary Image (black & white)

The gray scale image represents matrix of intensities value between (0 - 255), in this phase these value will be changed to binary value (0 , 1) by replacing all pixels in the input image luminance greater than threshold with the value 1 (white) and replacing all remaining pixels with the value 0 (black).

102	86	55	34	24	21	22	11
105	104	85	67	52	44	44	19
101	109	102	93	82	77	81	44
99	103	102	101	97	102	114	80
105	101	100	102	104	117	136	107
115	97	90	90	91	105	126	106
129	111	99	90	80	83	99	77
148	136	126	114	97	95	108	75
162	159	157	151	140	143	159	114
170	170	173	172	166	174	193	147
167	167	168	166	158	163	181	142
136	139	144	142	131	132	147	118

Figure (3.13) Part of Matrix for Gray Scale Image.

1	1	1	1	1	1	1	1	1	1	1
0	0	1	1	1	1	1	1	1	1	1
0	0	1	1	1	1	1	1	1	1	1
1	1	1	1	1	1	1	1	1	1	1
1	1	1	1	1	1	1	1	1	1	0
1	1	1	1	1	1	1	1	1	1	0
1	1	1	1	0	1	1	0	1	1	0
1	1	1	1	1	1	1	0	1	1	0
1	1	1	1	1	1	1	1	1	0	0
1	1	1	1	1	1	1	1	0	0	1
1	1	1	1	0	0	1	0	0	0	1
1	1	1	1	1	0	0	0	0	1	1
1	1	1	1	1	0	0	1	1	1	1
1	1	1	0	0	1	1	1	1	1	1
0	0	0	0	0	0	1	1	1	1	1
0	0	0	0	1	1	1	1	1	1	1
0	0	0	0	1	1	1	1	1	1	1

Figure (3.14) Part of Matrix for Binary Image.

The function:

```
Binary-image=im2bw(image-name,0.66);
```

`im2bw` : it is function converts gray scale image to a binary, if image was colored, the image will be changed to gray scale then to binary.

Binary-image: the gray scale image of blood smears had been created in last step.

(0.66) : this represents the threshold value, which has been assigned by trying.

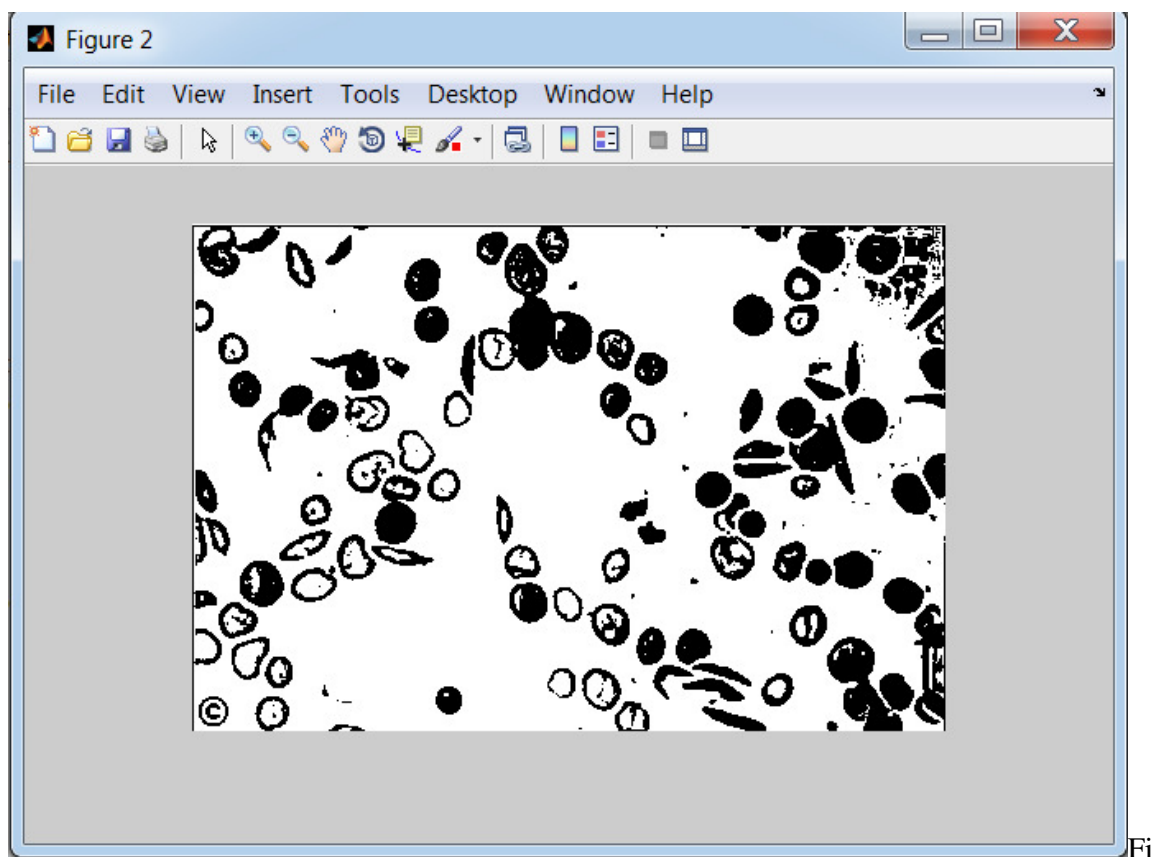


Figure (3.15) Binary Image Using (im2bw) Function.

After changing the image to binary, background has been colored white and the object has black color, but the function of boundary tracing depends on the pixel of regions that has value of (1) white color, that means the function will be traced the background instead of objects so the complement image will be created using the following function:

```
complemen-image=imcomplement(image-name);
```

imcomplement: it is a function to get the complement of the image, the 1s will be 0s And versa.

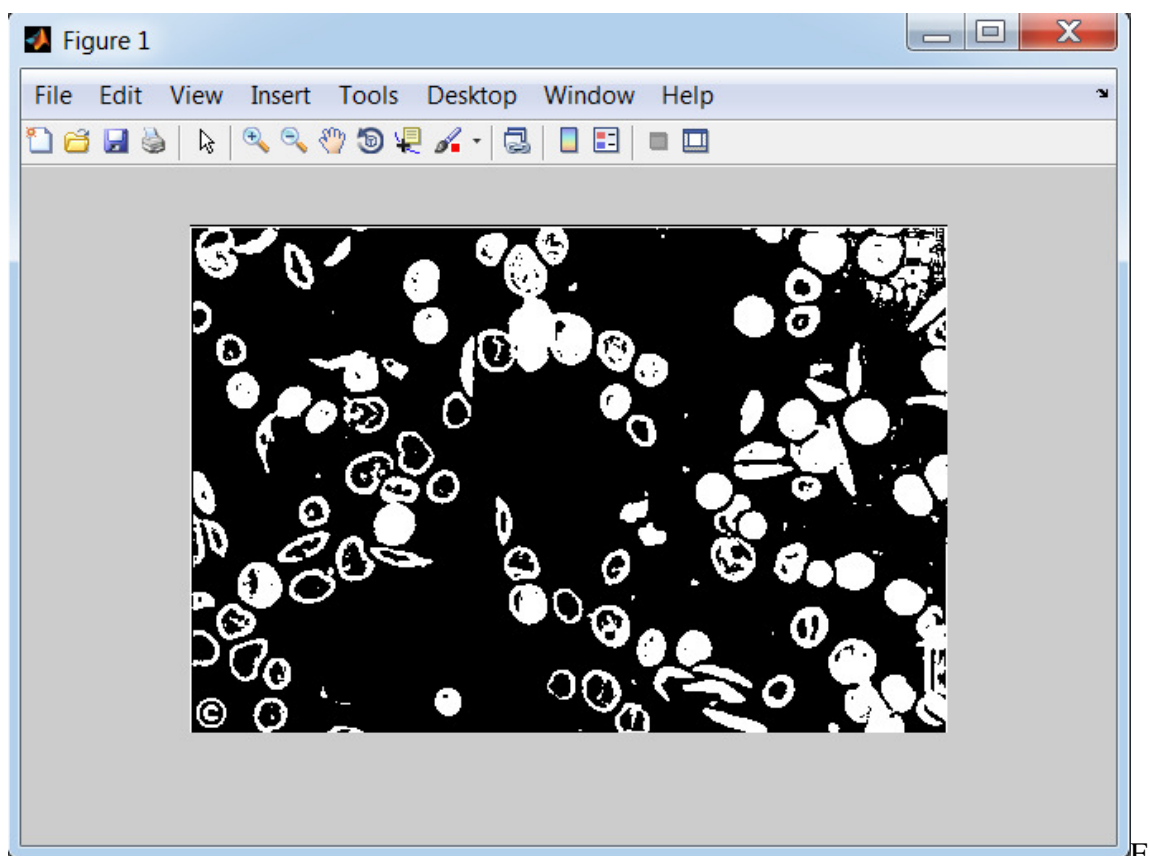


figure (3.16) Complement of Binary Image Using (imcomplement) Function.

### 3.2.2.5 Removing Small Objects

One of the preprocessing steps is data reduction and removing the noise before starting image processing, because when removing all small objects the image will be better to analysis. Blood smear image includes red blood cells, white blood cells and platelets, which is differentiated in the area (very small, small, medium, large and very large) this work confused on red blood cells, we should use methods to remove those very small objects, and the image of blood is stained with a special stain which affects the image, and may keep some noise in the picture, which will be removed in this process.

The very small area was estimated by trying results of dividing the magnification value by number ten. After the area of small objects has been computed will be away of the image using (bwareaopen) function as shown below:

The Function:

$I = \text{magnification value} / 10;$

`new-image=bwareaopen(image-name, objects-area);`

objects-area: is the area (pixel) of the small object, it has been assigned by trying (mag1/10).

image-name: is the complement of original binary image.

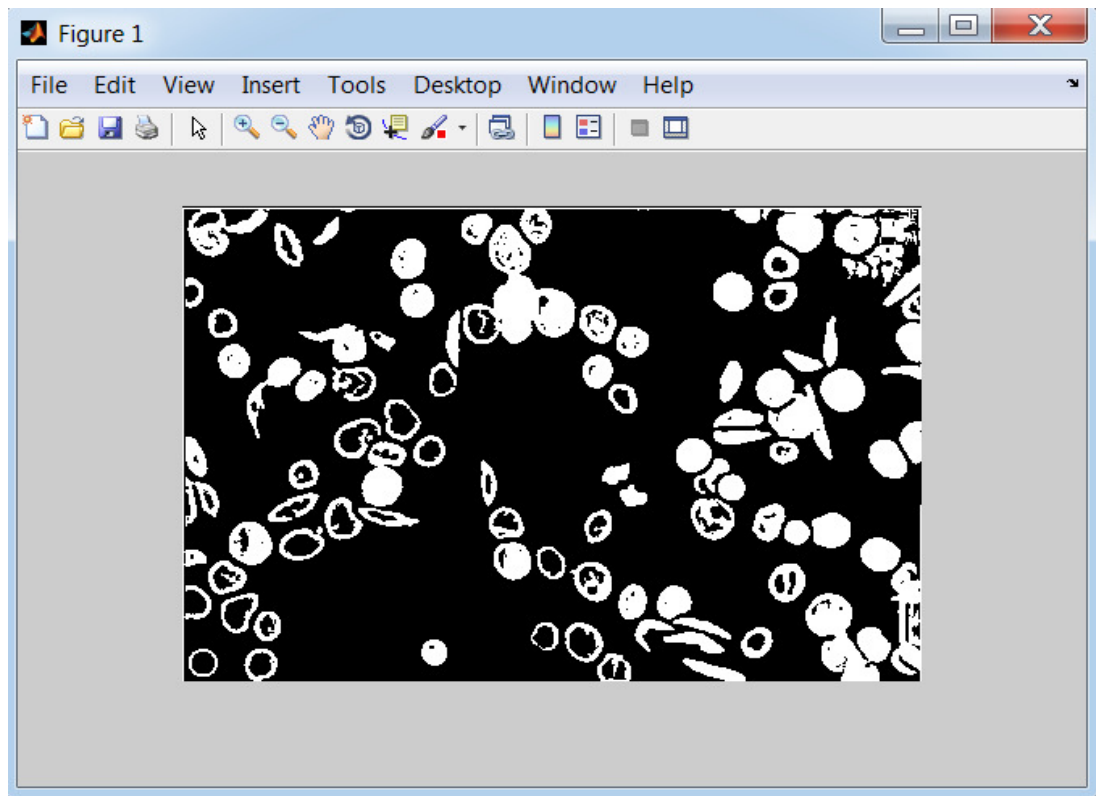


Figure (3.17) Binary Image after Remove Small Object

#### 3.2.2.6 Regions Boundary Tracing

This step is the process of division or separation the RBC's from their background, and Removing the borders touching cells obtained in binary image, and then performing the separation of each one of the RBC's as a labeled regions (sets of pixel) to be into something more meaningful and easier to analyze the informations and features that already exist in the cells.

The image function ( `bwboundaries` ) must be a binary image where nonzero pixels belong to an object, and zero pixels constitute the background, never the less it traces the exterior boundaries belonging to the (RBCs), as well as boundaries of holes inside these objects, in the binary image also descends into the outermost objects (parents) and traces their children's objects completely enclosed by the parents).

The Function:

`[B L N A] = bwboundaries (image-name, 4,'noholes');`

- `bwboundaries`: a function tracing the boundaries to localize the regions.
- number (4): are a connectivity
- (Holes): are options of tracing the boundaries of holes inside the object (RBC's) but with no holes option function is tracing the boundaries of RBCs just without holes.

### 3.2.2.7 Removing Incomplete Objects at the Boundary of the Image

There are an incomplete blood cells at the boundary of the image that exist while taking image for field of blood smear in preparation time , which doesn't carry useful information, so it will be removed from the image, There are two steps in this process :

- Finding the area that contains the region of the cells at the boundary.
- Making the pixel index of these regions 0 (black).



The Function:

- Compute image size ..... image size (1)=  $x_2$  & image size (2) =  $y_2$
- For  $I = 0$  to last element
  - Compute regions properties (bounding box) for each element
  - Compute  $x$ ,  $y$ , high, width for bounding box
  - If  $x$  less than 3 make each pixel index list for regions = 0
  - If  $y$  less than 3 make each pixel index list for regions = 0
  - If  $(x + \text{width})$  less than  $(\text{image size}(2) - 3)$  make each pixel index list for regions = 0
  - If  $(y + \text{high})$  less than  $(\text{image size}(1) - 3)$  make each pixel index list for regions = 0

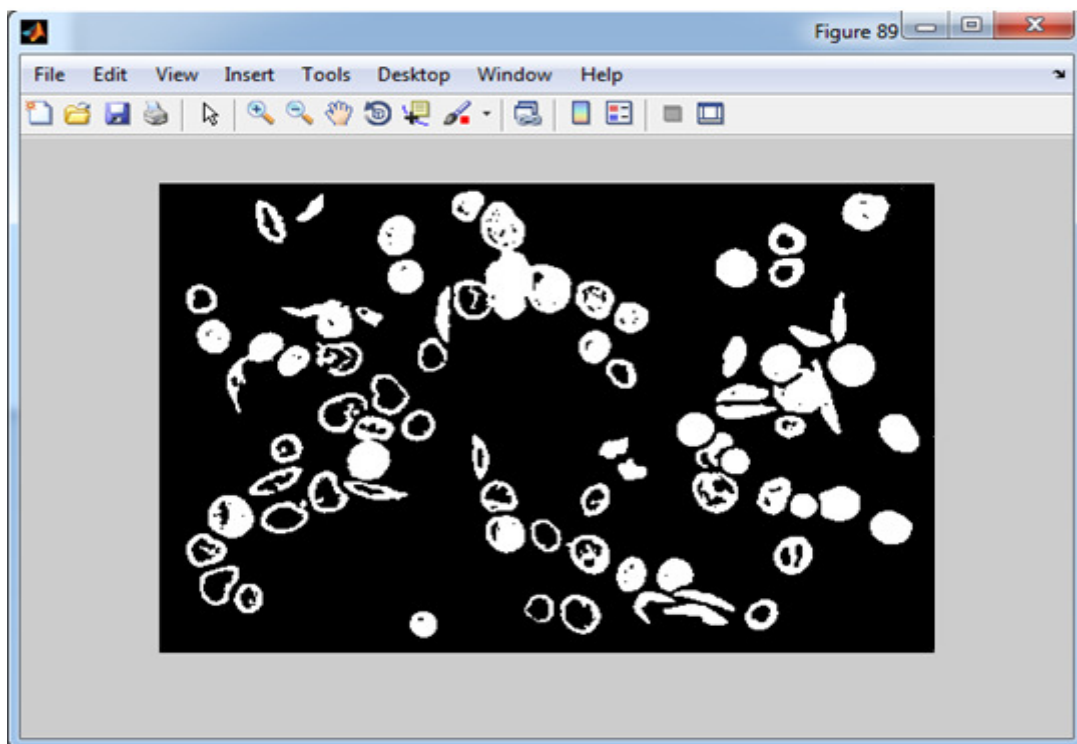


Figure (3.18) Binary Image after Removing Incomplete Objects at the Boundary.

### 3.2.2.8 Removing Intersected Cells

The intersection of red blood cells usually come in a view with the images in a range of overlapping degree, removing intersected cells will not affect the results accuracy because the system can analyze multiple fields of images and collects the results as counts and percentages which raise the accuracy of the results, the intersected cells size is larger than of the single cell, it means that the size is the main factor of localization the intersected cells.

The function

- For  $I = 0$  to last element
- Compute regions properties (bounding box) for each element
- Compute length for regions
- If width bigger than or equal of  $(\text{magnification} / 13)$  OR high bigger than or equal  $(\text{magnification} / 13)$ .
- make each pixel index list for regions = 0

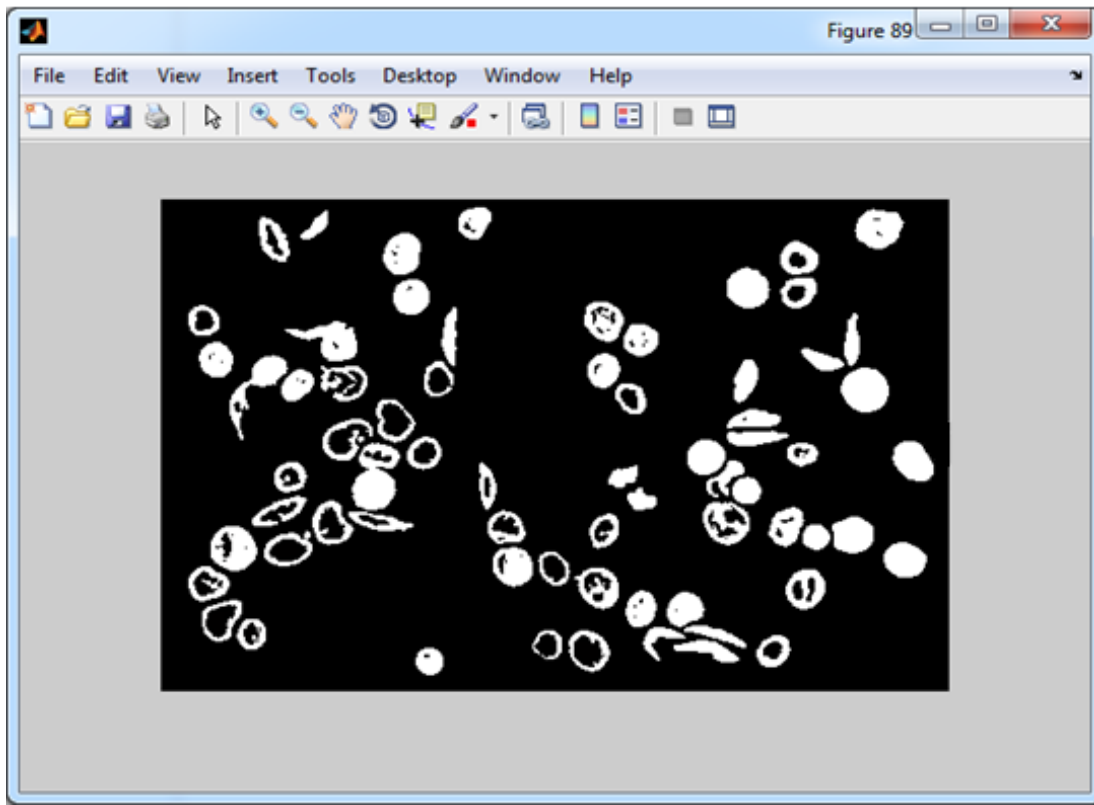


Figure (3.19) Complement of Binary Image after Remove Intersected Cells.

### 3.2.2.9 Creating Binary Image Depending on Red Scale Image

Some of the cells have buddies inside, that are tracing to be segmented and feature extracted to recognize some type of cells that have inclusion, so the red scale will be created, The red scale image represents matrix of intensities value between (0 - 255).

The red scale for regions used to measure the red scale in the RBCs using the function below:

$I = \text{im2bw}(\text{image name} (:, :, 1), \text{threshold value})$

- Creating image with red scale and the (0.5) is the threshold.
- Creating image with red scale and the (0.98) is the threshold.
- Creating image with red scale and the (0.4) is the threshold.

### 3.2.3 Feature Extraction

After inserting the image of sample on the computer system, then enhancing that, the feature will be extracted from the image. Feature extraction is the phase in which we are getting the information that is important to us from the image studied, in this work the method extract the features for each labeled region (cell area) and compute geometric shape features (area, Major/Minor Axis length, circularity, Bounding Box, Center), Variation in erythrocyte color, Inclusions and nucleated for each cell as shown below:

#### 1- Geometric Shape Features

A) Area: it is the number of pixel for each regions, the variation in area of the regions used to recognize the size of RBCs which vary in the size. The average size of an RBC is  $7.2 \mu\text{m}$  with a range of  $6.8$  to  $7.5 \mu\text{m}$ . When the magnification is computed the area for each cell will be computed, then we can distinguish them.

The function:

`area_temp1 = area1 (i).Area;` The area function returns number of pixels.

### B) Major Axis Length and Minor Axis Length:

Major Axis length: is the longest diameter of the region (length in pixels).

Minor Axis length: is the shortest diameter of the region (length in pixels).

The function:

Major Axis length

`maj_axis1 = majax1 (i) .MajorAxisLength;`

Minor Axis length

`min_axis1 = majax1 (i) .MinorAxisLength;`

### C) Circularity: it is measured by calculating the ratio between the Major Axis length on Minor Axis length, If the result is almost one so the shape tends to be circular.

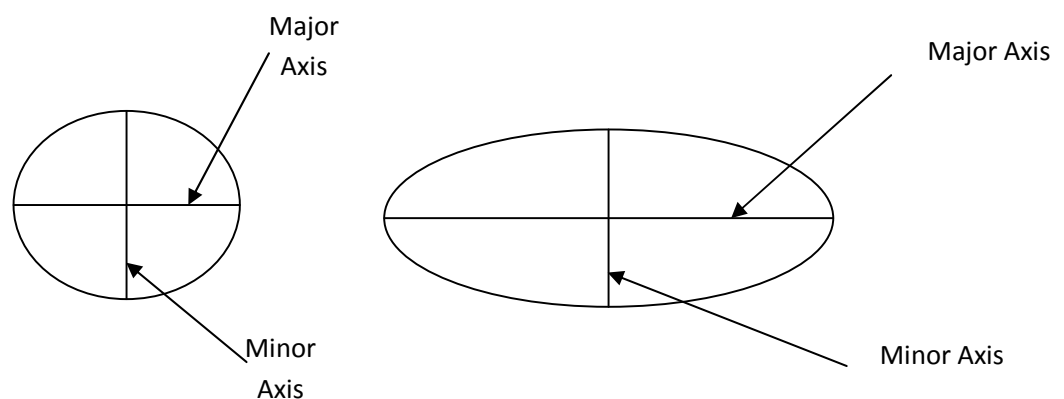


Figure (3.20) Circularity for the Region and Major/Minor Axis.

The function:

`Ratio1 = maj_axis1/min_axis1;`

Note: if ratio equal one then the shape is circle.

D) Bounding Box: The smallest rectangle containing the region

The function:

```
box_temp1 = box (i).BoundingBox;
```

(BoundingBox) function returns array include four elements [X,Y,W,H], x and y are the coordinate for the start point of the rectangle and w is width h is high as shown in figurer (3.13).

E) Center: the Center of Mass of the Region

- The bounding box center: the center of the box is the central point in the box, which represent as these equations:

$$a = x + (w/2)$$

$$b = y + (h/2)$$

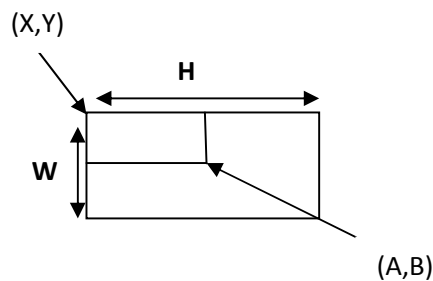


Figure (3.21) Center Point for Bounding Box.

- The Regions Center

```
Function: center1_temp = centroid1(i).centroid;
```

Note: (centroid) function returns coordinates of the center (a, b) as view in the shape below:

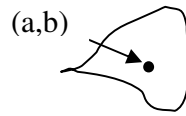


Figure (3.22) Center Point for the Region.

## 2- Variation in Erythrocyte Color:

The RGB-image is a color image contains three layers: the first layer red scale, second layer is Green scale, and the third layer is blue scale. The RBCs, each layer has scale between (0-255).

The green color wasn't used for all regions just in the target cells which used to classify the target cell by measuring green scale of the center point using the (impixel) function that return three value (Red layer value, Green layer value, Blue layer value) for specific point as shown in the function is: `color2 = impixel (imgrgb1, center1_x, center1_y);`

## 3- Inclusions and nucleated

The some of RBCs have inclusion (Holly body, Reticulocytes, Basophilic stippling) or nucleated (nucleated cells).

### 3.2.4 Red Blood Cells Classification

In this phase the feature extracted will be pass by the algorithm and measuring these features to identify the types of the RBCs. There are many conditions for each RBC used to be classified as shown below:

1- Sickle cells: it is s shaped with crescent usually one end pointed, and it is varying in size but it is usually smaller than the normal RBC.

[Function]RBCs will be classified as sickle cell if:

- The region is irregular in shape, and it has been tested by computing the distance between the center of bounding box of the region and the center of the region (cell body) either on the x\_axis or y\_axis, if the distance is great, so it is a irregular shape but if the distance is too close so it is a regular shape.
- The color of the region center more than 10 of 255 for each RGB-layer this makes analysis more accurate and be sure that no gap or hole in the regions.
- Area is smaller than minimum area of normal RBCs and more than 0.1 of minimum area of normal RBCs which makes sure that region represents true RBCs.

2- Elliptocytes: is characterized by its elliptical shape for this reason it is called elliptocyte and it varies in size, but usually bigger than the normal RBC.



[Function] RBCs will be classified as Macrocyte cell if:

- Ratio more than (1.75) to be sure that the region has Oval status. And region has regular forms.
  - Area ranges between (1.3) of minimum normal RBCs area and (1.3) of maximum normal RBCs area).
  - The green layer value in RGB-image of the region center and the region center plus three and minus three on (( x and y) axis) less than 180).
- 3- Macrocyte: featured with increase in the size of a red blood cell. Red blood cells are larger than  $9\mu\text{m}$  in diameter, May be round or oval in shape, the diagnostic significance being different.

[Function]RBCs will be classified as Macrocyte cell if:

- Ratio of the region less than (1.2) to be sure that the shape is circular.
  - The area of region larger than the maximum area of normal RBCs.
  - The green layer value in RGB-image of the region center and the region center plus three and minus three on (x and y axis) between (100- 200).
- 4- Target cells: it is Red cell with a “target” or bull’s-eye appearance.

The hole that inside cells has been identified using red scale with threshold value of (0.89) to segment hole of the cells, and then its (center, major / minor axis length, and area) will be extracted.

[Function] RBCs will be classified as Target cell if:

- Ratio of the region less than (1.2) and the ratio of internal hole less than (1.6).
  - The area of region bigger than the maximum area of normal RBCs, and The area of the internal region hole is larger than 30 pixels and less than double minimum of the normal area cells.
  - Distance between center of internal region and center of region less than radius of region cell.
  - The green layer value of the region center or the region center plus three or minus three on (x and y axis) is between (100 - 200).
- 5- Microcytic and hypochromic cells: are characterized by circular small size but are usually specialized having pallor tends to whiteness inside it.

[Function]RBCs will be classified as a Microcytic and Hypochromic cells if:

- Ratio for region is less than (1.2) and area is smaller than 0.85 of minimum area and bigger than 20 pixel and green layer of RGB color for the center region is more than 140; this condition affirms that the color of the center is pale in color.
- 6- Spherocytes: are shaped with more spherical, lack the central area of pallor on a stained blood film.

[Function] RBCs will be classified as Spherocytes if:

- Ratio for region is less than (1.2) and area is smaller than (0.85) of minimum area and bigger than 20 pixel to be sure that it's a true cell.
  - Green layer of RGB color for the center of spherocytes is less than 140 and red layer value more than 140; this condition makes sure that the color of the center is not pale.
- 7- Teardrop cells: are featured with tear shape, and their size is bigger than the minimum normal cell size.

[Function]RBCs will be classified as teardrop cell if:

- Ratio is between (1.2 – 2.2) and the shape is Irregular.
- Area of region cell is bigger than 1.7 of minimum area of normal RBCs and less than (1.7) of maximum area of normal RBCs.
- The green layer value in RGB-image of the region center and the region center plus three and minus three on (x and y axis) less than 180).

In the Holy jolly cells, Basophilic stippling cells, and Reticulocytes classification; the small bodies inside cells have been identified using red scale with threshold value of (0.5) to segment hole of the cells, and then its (center, major / minor axis length, and area) will be extracted.

- 8- Howell- Jolly cells: it has round objects, dark blue color. When present, there is only one or two per red cell.

[Function]RBCs will be classified as Holy jolly cells if:

- Ratio is less than (1.5) and area of cell region is bigger than 1.3 of minimum area of normal RBCs and smaller than maximum area of normal RBCs, and area of round objects bigger than  $(\text{magnification} / 125)$  and smaller than  $(3 * (\text{magnification} / 125))$ .
  - The round buddies found one or two in each cell and Making sure of the existence objects within the cell.
  - Blue layer of RGB color for the center of round objects is more than (70).
- 9- Basophilic stippling cells: are having purple-blue granules, they are evenly distributed throughout the red blood cell.

[Function] RBCs will be classified as basophilic stippling if:

- Ratio is less than (1.5) and Area of cell region bigger than 1.3 of minimum area of normal RBCs and smaller than maximum area of normal RBCs and the area of round buddies bigger than  $(\text{magnification}/125)$  and smaller than  $(3 * (\text{magnification} / 125))$ .
- The purple-blue granules were found more than two and less than nine in each cell, and the buddies have affirmed the existence within the cell. Blue layer of RGB color for the center of reticular is more than (70).

- 10- Reticulocytes: are having reticular with dark blue color, they are evenly distributed throughout the red cell as a reticular; it does not look like basophilic stippling.

[Function]RBCs will be classified as Reticulocytes if:

- Ratio is less than (1.5) and area of cell region bigger than 1.3 of minimum area of normal RBCs and smaller than maximum area of normal RBCs and area of round buddies bigger than (magnification /125) and smaller than (3 \* (magnification / 125)).
- The reticular with dark blue color found more than nine in each cell, and the buddies have affirmed the existence within the cell. Blue layer of RGB color for the center of reticular is more than 70.

- 11- Stomatocyte: it is featured with a circular shape that has a hole which looks like a mouth very bright red color.

The hole that inside cells have been identified using red scale with threshold value of (0.89) to segment the hole of the cells, and then its (center and distance between “the center of the cell region and the center of the holes) will be extracted.

[Function] RBCs will be classified as stomatocyte if:

- Ratio for region is less than (1.5).
- Distance between (region center and the hole center is shorter than the radius, that means that the hole is followed to the same cell region).

- Hole area should be bigger than 50 pixels and smaller than double of maximum area for normal RBCs that's to avoid regions that don't assimilate true hole.

12- Nucleated: it is featured with a semi-circular shape that has a nucleated which has circle shape and dark blue color.

The nucleus that inside cells have been identified using red scale with threshold value of (0.4) to segment nucleus of the cells, and then its (center and distance between “the center of the cell region and the center of the nuclei) will be extracted.

[Function] RBCs will be classified as nucleated cell if:

- The ratio for region and the ratio for nucleated are less than (1.5).
- The distance between (region center and the hole center) is shorter than the radius that means that the hole is followed to the same cell region.
- Nucleated area should be bigger than 0.7 of minimum area of normal RBCs, and the area of nucleated should be less than  $1.5 * (\text{cell area} - \text{nucleated area})$  that to be distinct from some kind of WBCs.

### 3.2.5 Results

Lastly after developing computer-based information, the results will be computed and represented which aimed to enhance blood anemia diagnosis, so the main results consist of into three main points:

- 1- Classifying each cell alone: the system classifies cells after extracting properties and examining them in 12th kinds we have studied.
- 2- Computing the number of cells for each kind: system counts number of cells for each kind alone which helps counting percentages.
- 3- Computing the percentage of cells number: depending on cells number that were examined and classified and the number of cells in each kind, this system counts the percentage of each kind depending on the whole number of cells that were examined.

The characteristic of this system is that it supports the property of varied photos personification which also helps in results punctuality and giving clear, useful results to anemia disease.

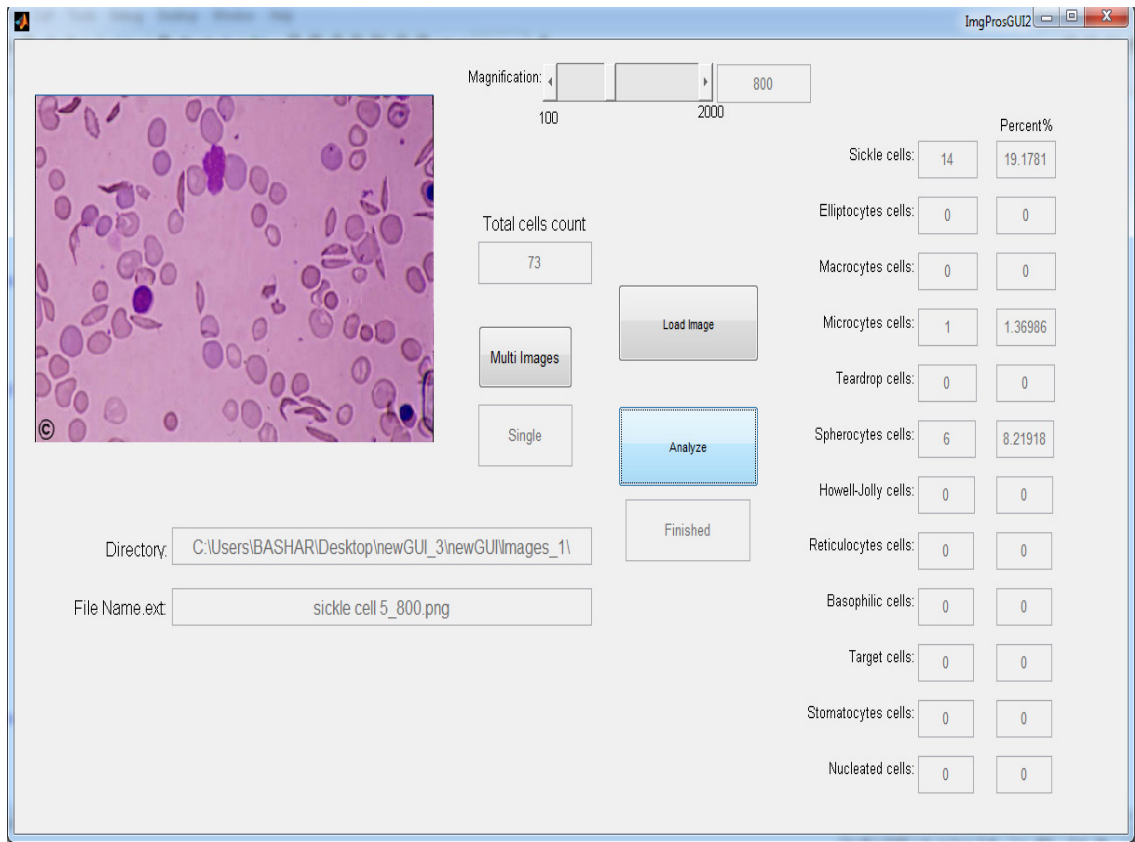


Figure (3.23) Result Screen.



## **Chapter Four**

### **Results and Discussion**

The system has been constructed based upon identifying the 12 different types of red blood cell (RBCs). Identifying the percentage of these types leads to a more accurate diagnosis of many anemias.

#### **4.1 Comparison of this System with Previous Works and Discussion**

Peripheral blood smear image processing has widely invaded the field of diagnostic medicine. The blood is primarily composed of three formed blood elements; red blood cells, white blood cells, and platelets. Numerous computerized systems have been developed in order to recognize these different cells .Knowing that RBCs compose the majority of blood cells, gathering as much information as possible about them can provide very appealing outcomes. Several previous papers have tackled the process of blood film analysis each with its pros and cons, but an ideal computerized system has not yet been developed for differential recognition of blood cells.

##### **➤ Cell Segmentation**

Bikhet, Darwish, Tolba & Shaheen (2000) worked on differentiation of normal WBC types based on their outer contour and nucleus shape. The system was based on the idea

that WBCs have darker and larger size than RBCs and platelets. It has used combined methods to separate the cells from the background while enhancing the outer and inner rims. A binary image was the final result. Lastly, the cells were classified into one or five WBCs types based on mean values of certain predetermined features. However, the system didn't address the abnormal WBCs which can be found in many hematological disorders.

Sharif, Miswan, Ngadi, Salam & Abdul Jamil (2012) discussed RBC segmentation. Firstly, they segmented the WBC nuclei. This was used as a mask to remove WBCs from the image. The resulted RBCs were processed further using certain markers. Though; the masking operation depended on extracting the WBC nuclei only, while leaving the cytoplasm. Furthermore, no discussion was made about how to identify abnormal RBCs or how to classify them.

Al-hadidi (2012), discussed diagnosing anemia based on small intestinal villi examination. The approach was based on the idea iron deficiency can cause the intestinal villi to lose their red color on staining. MATLAB software was used. Despite the high precision and complexity the system has technical wise, certain inadequacies existed medical wise. Getting intestinal biopsies is a rather drastic approach for such a readily approachable and treatable condition as iron deficiency anemia. This fact may have kept the system a rather theoretical approach far from the practical use. Moreover, deficient tissue iron may indicate to iron deficiency state rather than to iron deficiency anemia. The latter only complicates one third of the former. Besides, decreased intestinal villi iron could indicate to a malabsorption or to local problem in the intestines that is not necessarily complicated by iron deficiency anemia. Also, Iron deficiency anemia may causes other than

intestinal ones, like pregnancy for instance. In these states there is actually increase intestinal absorption of iron, a feature that can potentially give false positive results. Finally, tissue staining for iron makes it difficult for physicians to decide the mode and the aggressiveness of treatment the patient requires or his/her response to that treatment.

This system has uniquely provided means to identify RBC counts and abnormalities. Most of the previous work in that field was merely concentrated on detecting normal cell, whether white or red, without specifying their state. After acquisition and reading, images were pre-processed in order to remove the mistakes and making it ready for analysis. The final results were provided as RBC types, counts and percentages. At earlier stages, platelets and all types of impurities were removed in order not to influence the proper counts and percentages. This was accomplished by examining the size; as platelets and impurities are always much smaller than other cells. The system omitted all parts less than 0.1 in size of the magnification. This feature was not provided by any of the previous works.

A possible situation is that when platelets come within a cell region (in the image). Such platelets may resemble intracellular inclusions, like Howell-jolly bodies for instance. If traditional counts were used in this situation, false positive results may be obtained. This system provided very appealing solution by depending on color concentration to separate platelets from the underlying RBCs. Moreover, nucleated RBCs, found in certain types of anemia, exhibit great similarity to WBCs as both contain a nucleus. Using legacy systems, nucleated RBCs may be wrongly considered as a type of white blood cells. This system charmingly addressed that dilemma. Although these two types of cells look much the same,

they also have distinguishing features. We noticed that nucleated RBCs have relatively smaller nuclei and more plentiful cytoplasm compared to WBCs that have larger nuclei surrounded by a thin rim of cytoplasm. The areas of the nucleus and the cytoplasm in each nucleated cell were measured. Accordingly, RBCs were identified by the ratio of nucleus (major/minor axes), the red scale threshold and the nucleus area compared to cytoplasm area. All the aforementioned factors had effectively distinguished nucleated RBCs from their white blood cells counterparts. None of the previous works had utilized such approach in the field of RBC segmentation.

### ➤ **Overlapping Cells**

Overlapping cells may contain a great deal of diagnostic information, so the ability of the systems to handle such overlaps provides major advantage points. (Bikhet, Darwish, Tolba & Shaheen 2000) were not able to give acceptable solutions for overlapping cells. (Sharif, Miswan, Ngadi, Salam & Abdul Jamil, 2012) also, omitted these cells with whatever diagnostic clues it had. (Alhadidi, 2012) used algorithm provided greater ability in examining villi of interest. This feature can compensate for any improper sliding technique. Unfortunately, this system also struggled with this problem. However, after studying the benefits and disadvantages of incorporating overlapping cells into the counts, it was found that eliminating overlapping cells gives much better results than incorporating them.

### ➤ Boundary Cells

Boundary cells could be cells of potentially great diagnostic significance. None of the systems including this one did find reasonable theory to deal with these cells also. Again, incorporating these cells into the count can do more bad than good, a fact that necessitates removing cells in order to achieve better results.

## 4.2 Results

Making sure that our algorithm is working properly, tests were conducting on 12 images (taken of real blood smears); those images contained over (597) blood cells. Eventually the results were acceptable and comparable with the traditional visual counts. Below, the images used in testing the algorithm are illustrated, followed by the results acquired.

		Percent%
Sickle cells:	15	2.65957
Elliptocytes cells:	17	3.01418
Macrocytes cells:	7	1.24113
Microcytes cells:	25	4.43262
Teardrop cells:	12	2.12766
Spherocytes cells:	124	21.9858
Howell-Jolly cells:	3	0.531915
Reticulocytes cells:	2	0.35461
Basophilic cells:	2	0.35461
Target cells:	8	1.41844
Stomatocytes cells:	8	1.41844
Nucleated cells:	1	0.177305

Table (4.1) The result of tests were conducted on 12 images.

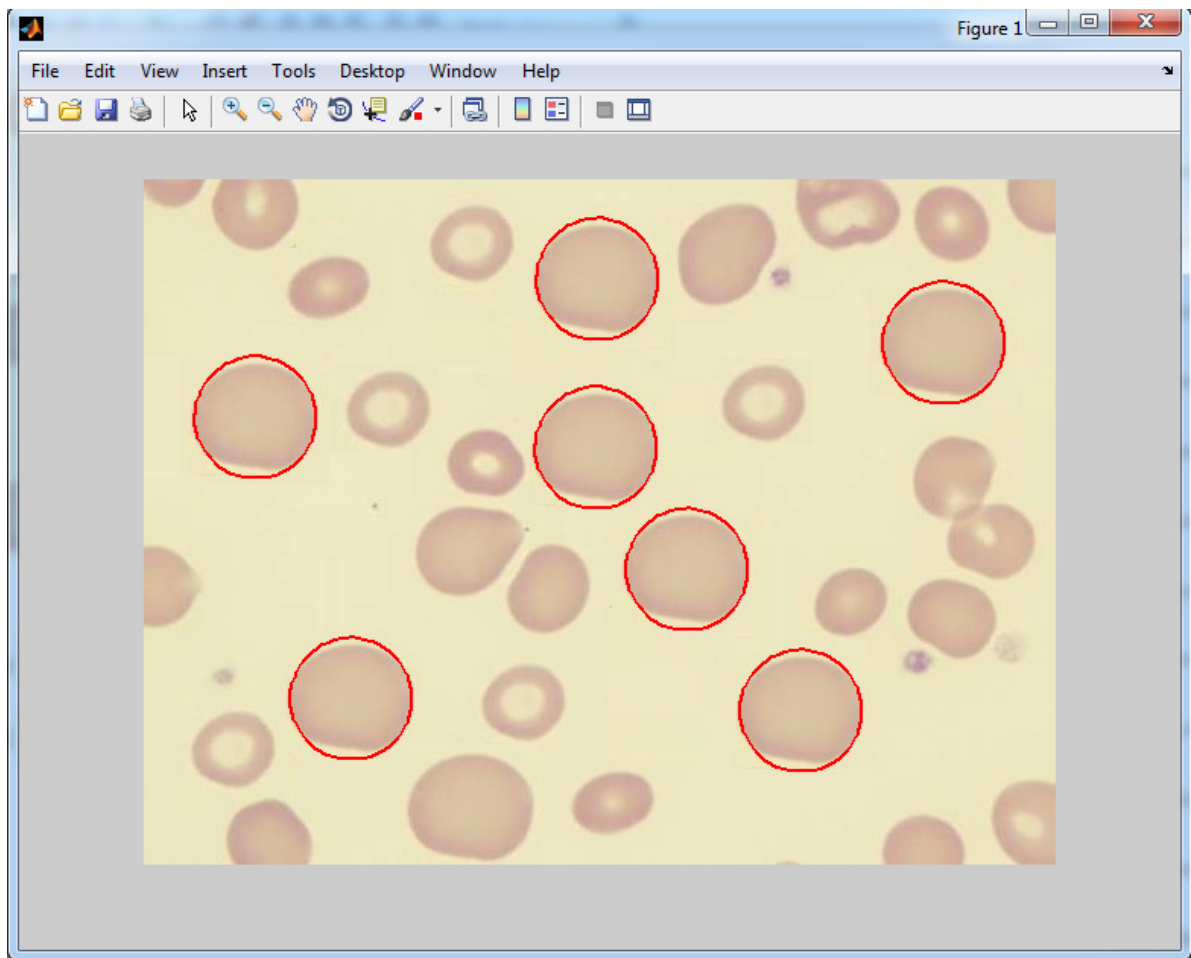


Figure (4.1) Macrocyte Identification.

After applying the system to the above image sample, the system found the following results:

- The total cell count is (23)
- (seven) Macrocyte with Percentage (30.4348 %)

These results can indicate to Vitamin b12 deficiency and Folate deficiency.

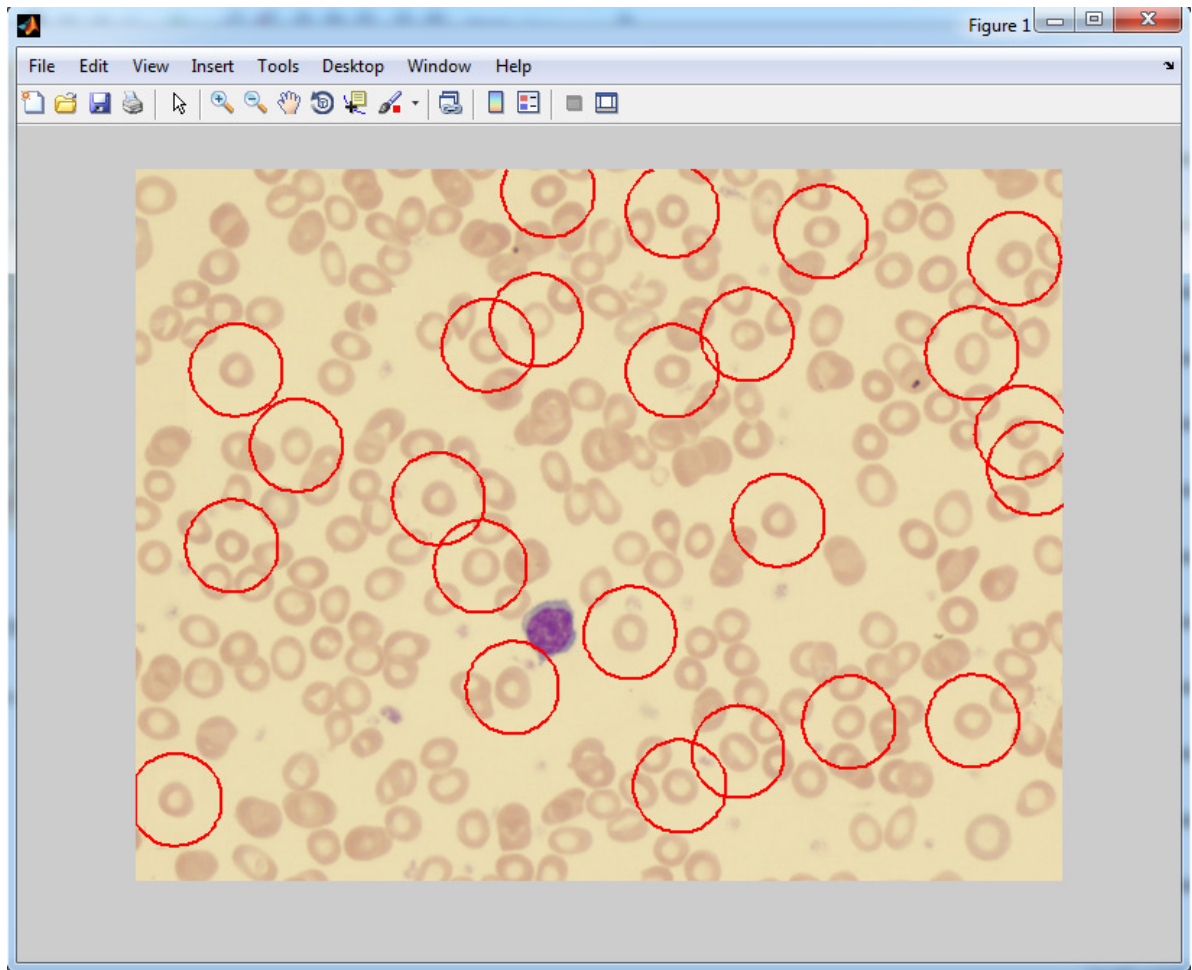


Figure (4.2) Microcyte Identification.

After applying the system to the above image sample, the system found the following results:

- The total cell count is (101)
- (24) Microcyte with Percentage (23.7624 %)

These results can indicate to (Iron deficiency, Thalassemia, Sideroblastic anemia).

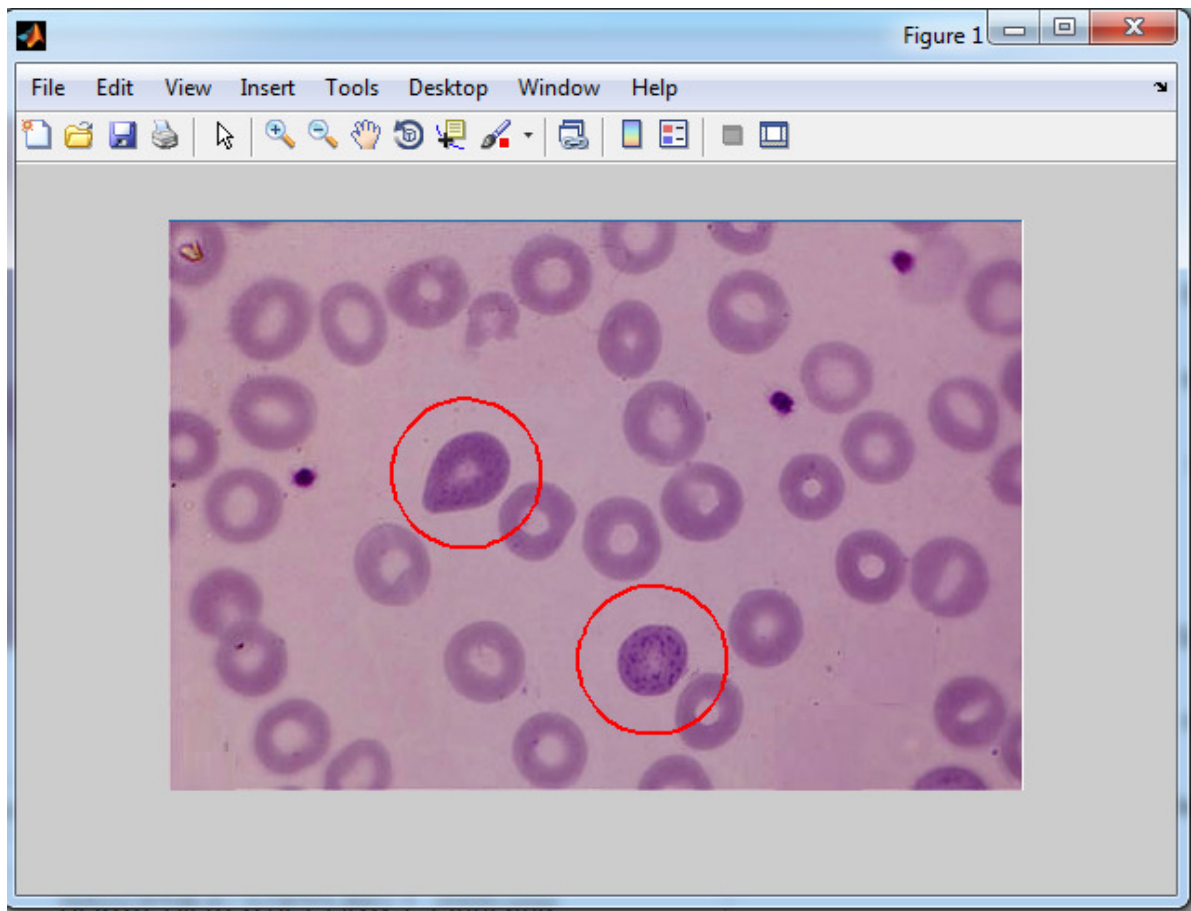


Figure (4.3) Basophilic Stippling Identification.

After applying the system to the above image sample, the system found the following results:

- The total cell count is (24)
- (Two) Basophilic stippling cells with Percentage (8.33333)

These results can indicate to Thalassemia as probable causes of the patient condition.



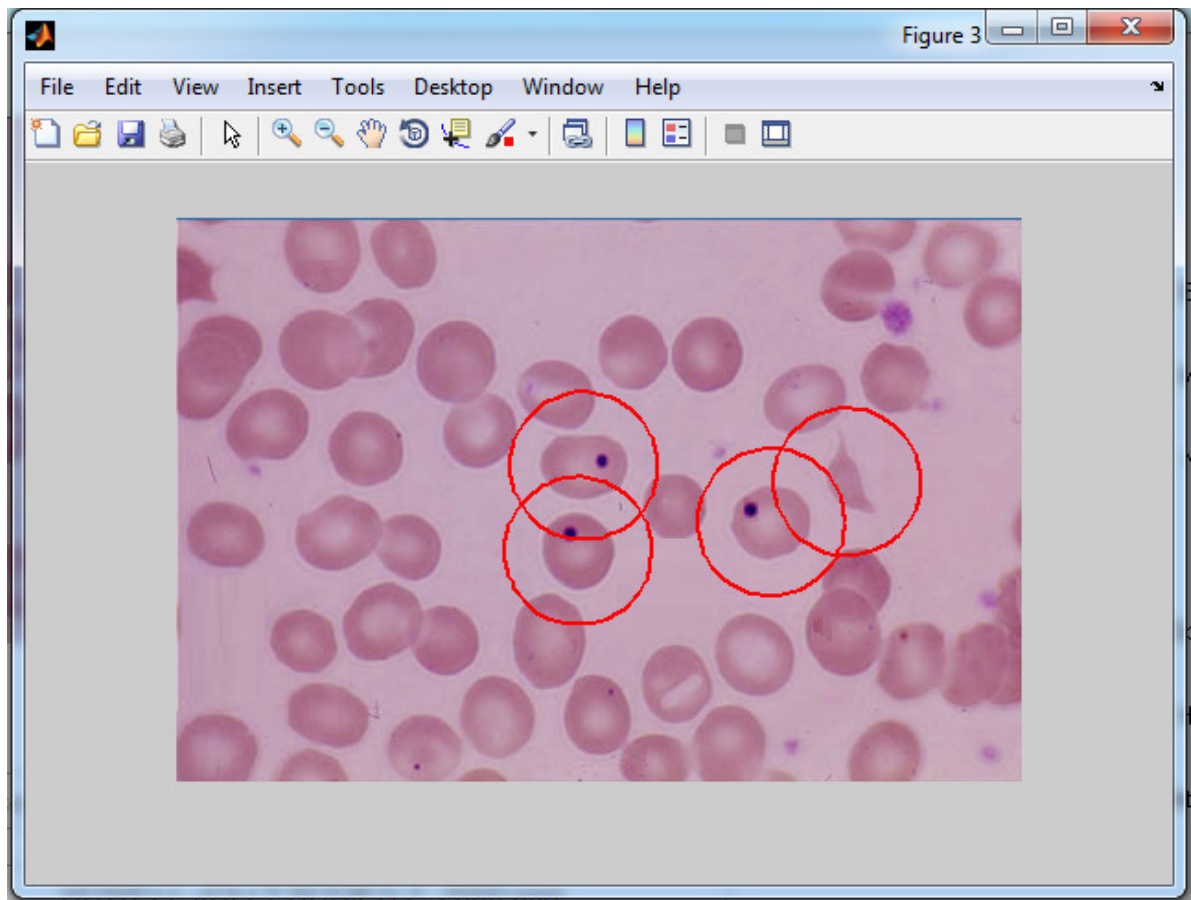


Figure (4.4) Howell- Jolly Body Identification.

After applying the system to the above image sample, the system found the following results:

- The total cell count is (22)
- (three) Howell- Jolly body with percentage (13.6364 %)
- Sickle cells (one) with percentage (4.54545%)

These results can indicate to (autosplenectomy caused by sickle anemia, severe hemolytic anemia, megaloblastic anemia)

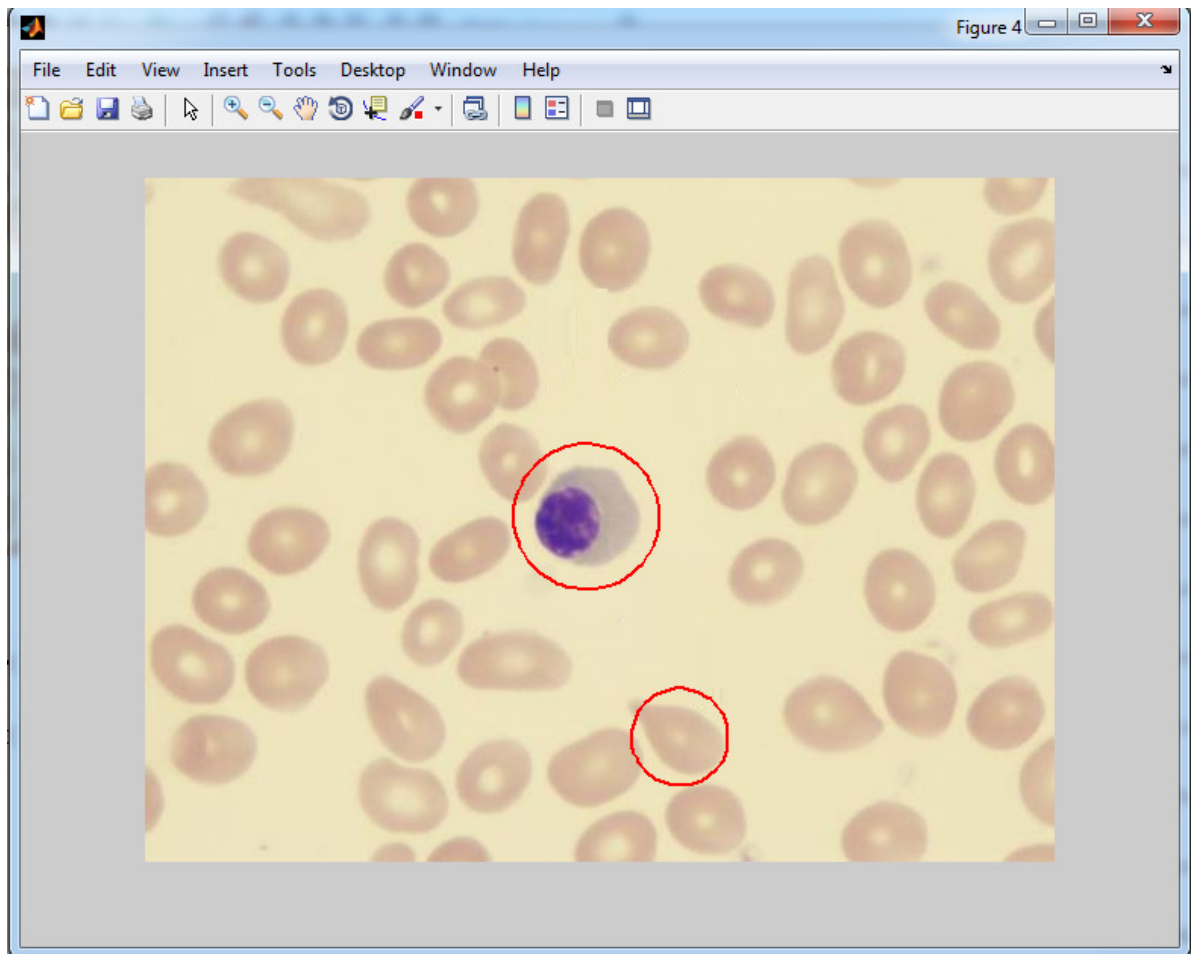


Figure (4.5) Nucleated and Teardrop Identification.

After applying the system to the above image sample, the system found the following results:

- The total cell count is 43
- (one) Teardrop cells with percentage 2.32558
- (one) Nucleated cells with percentage 2.32558

These results can indicate to (Hemolytic anemia, Thalassemia, Severe iron deficiency

anemia)

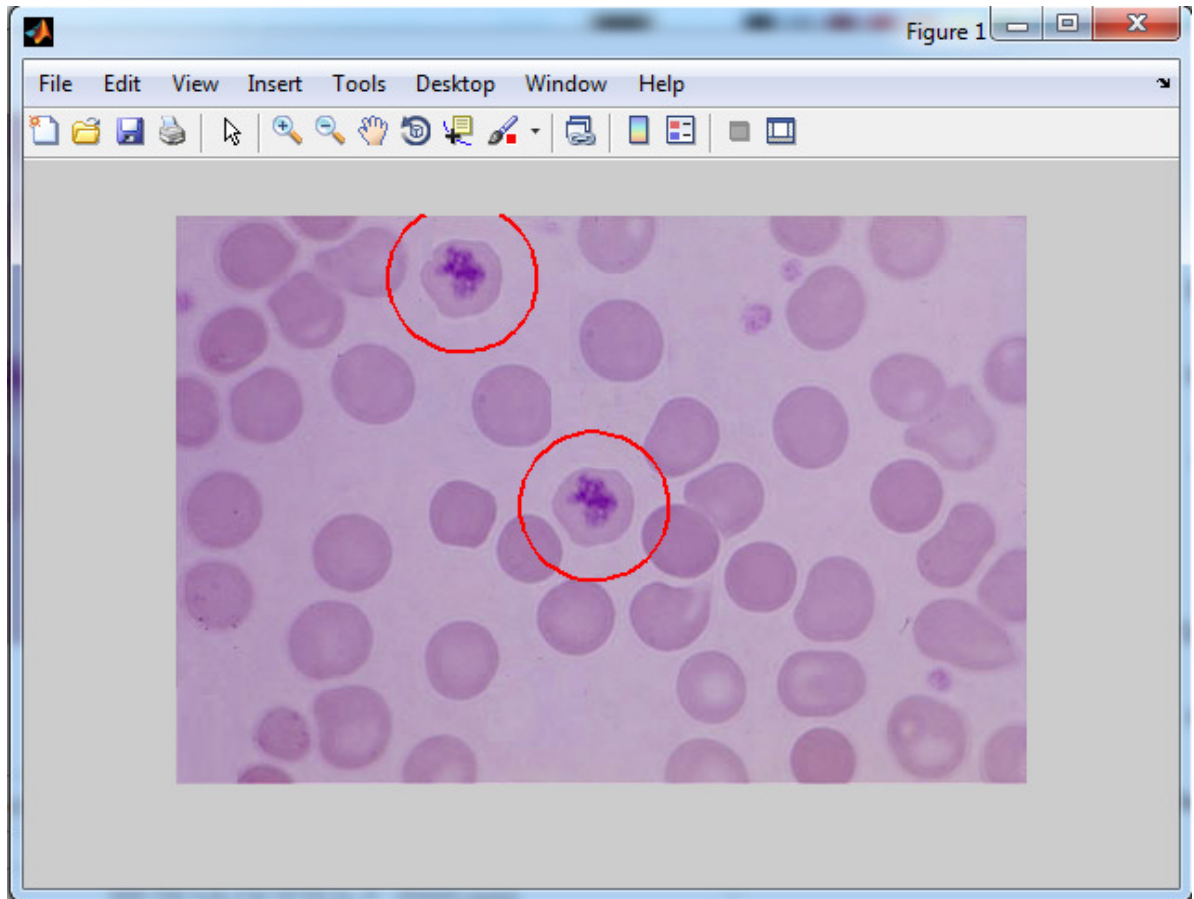


Figure (4.6) Reticulocytes Identification.

After applying the system to the above image sample, the system found the following results:

- The total cell count is (27)
- (Two) Reticulocytes with percentage (7.40741 %)

These results can indicate to hemolytic anemia

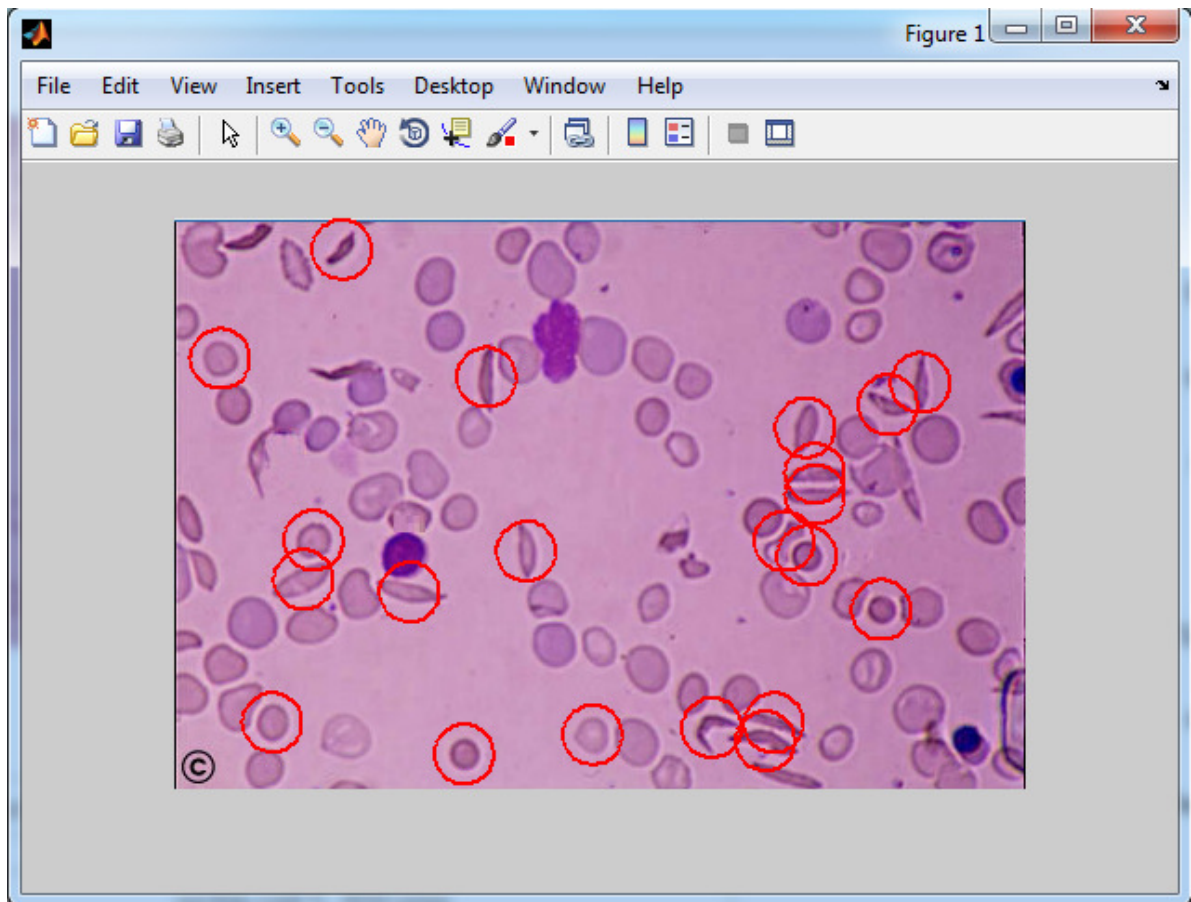


Figure (4.7) Sickle Cells Identification.

After applying the system to the above image sample, the system found the following results:

- The total cell count is (73)
- (14) Sickle cells with percentage (19.1781)
- (six) spherocytes with percentage (8.2191)
- (one) microcytes with percentage (1.3698)

These results can indicate to sickle cell anemia.

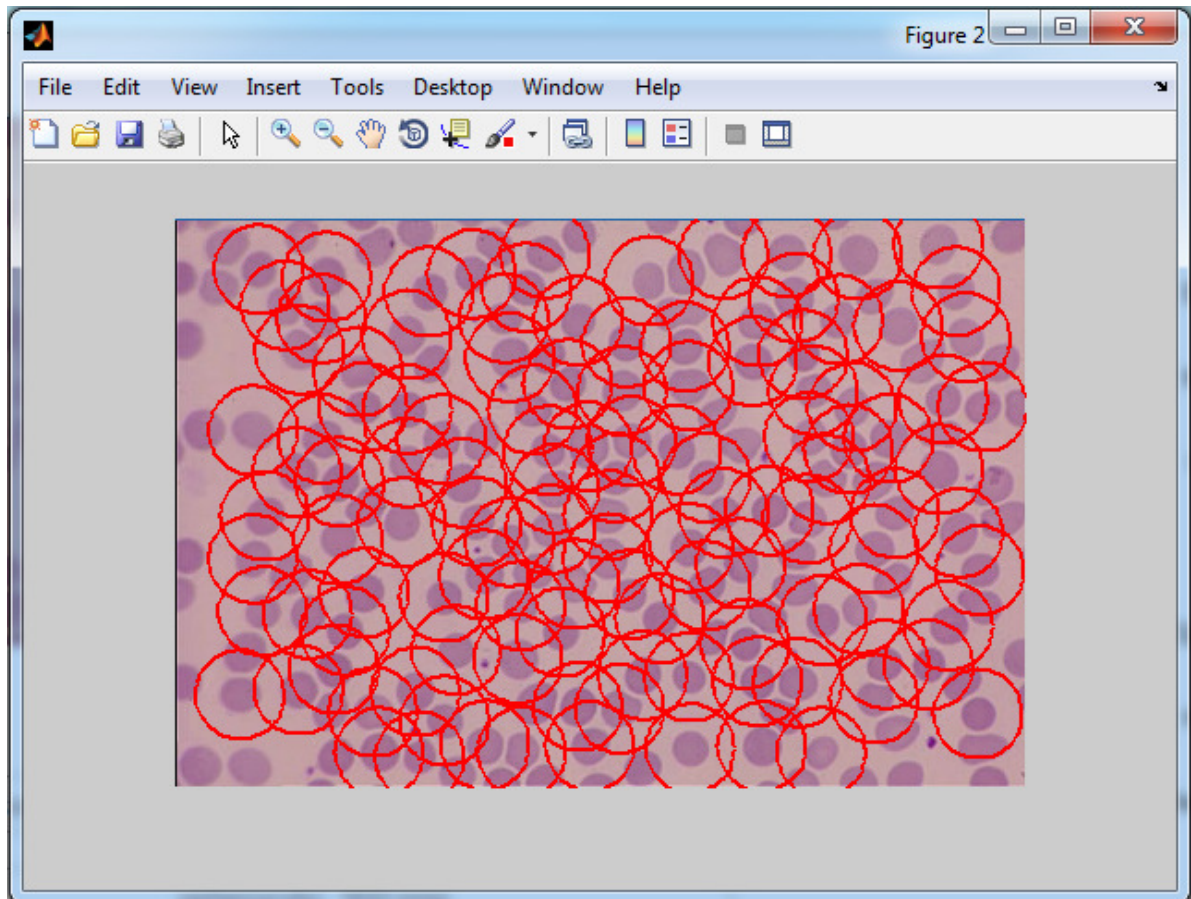


Figure (4.8) Spherocyte Identification.

After applying the system to the above image sample, the system found the following results:

- The total cell count is (149)
- (118) Spherocyte with percentage (79.1946)

These results can indicate to (Hereditary spherocytosis, Hemolytic anemia of other cause).



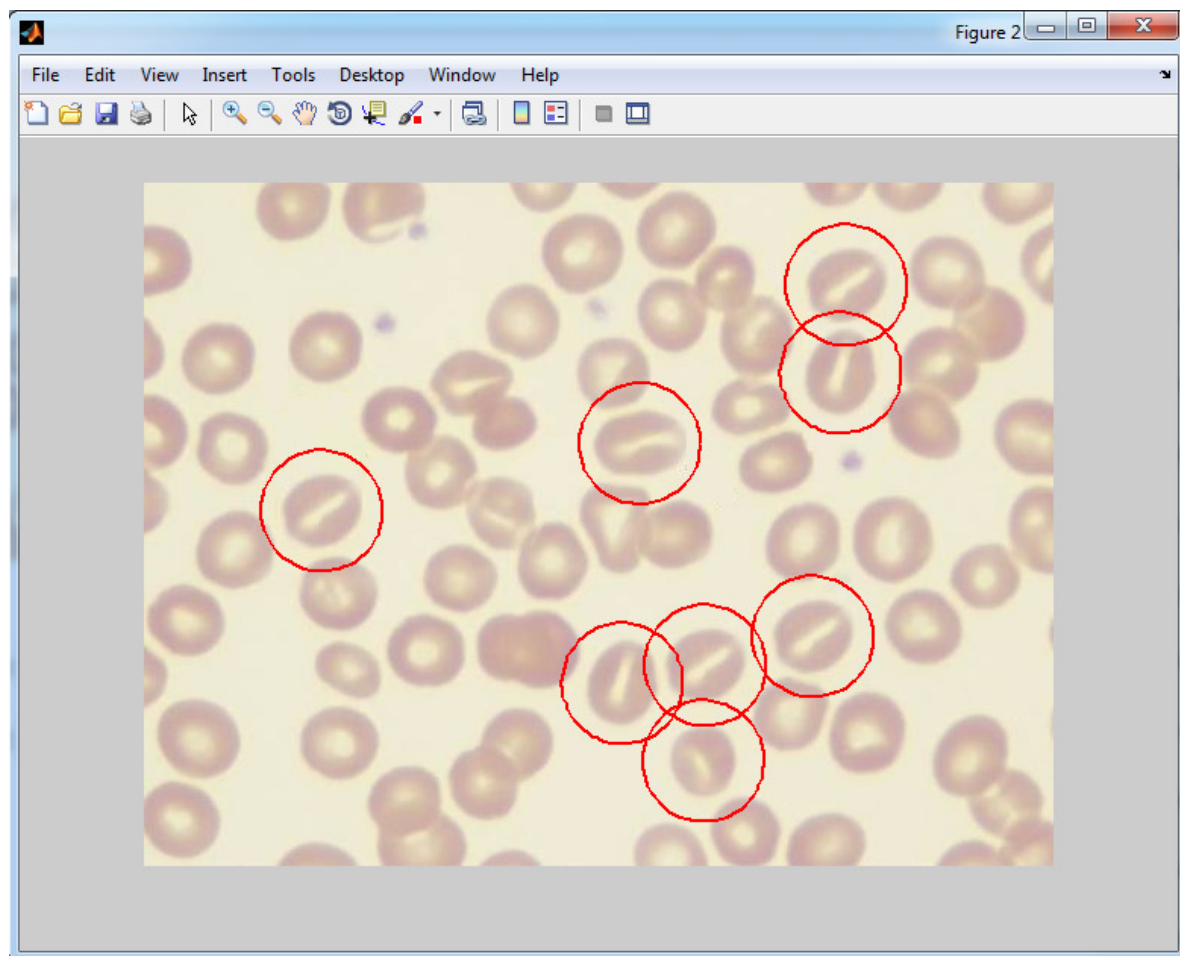


Figure (4.9) Stomatocyte Identification.

After applying the system to the above image sample, the system found the following results:

- The total cell count is (33)
- (Eight) Stomatocyte with percentage (24.2424)

These results can indicate to (Hereditary stomatocytosis, Alcoholism)

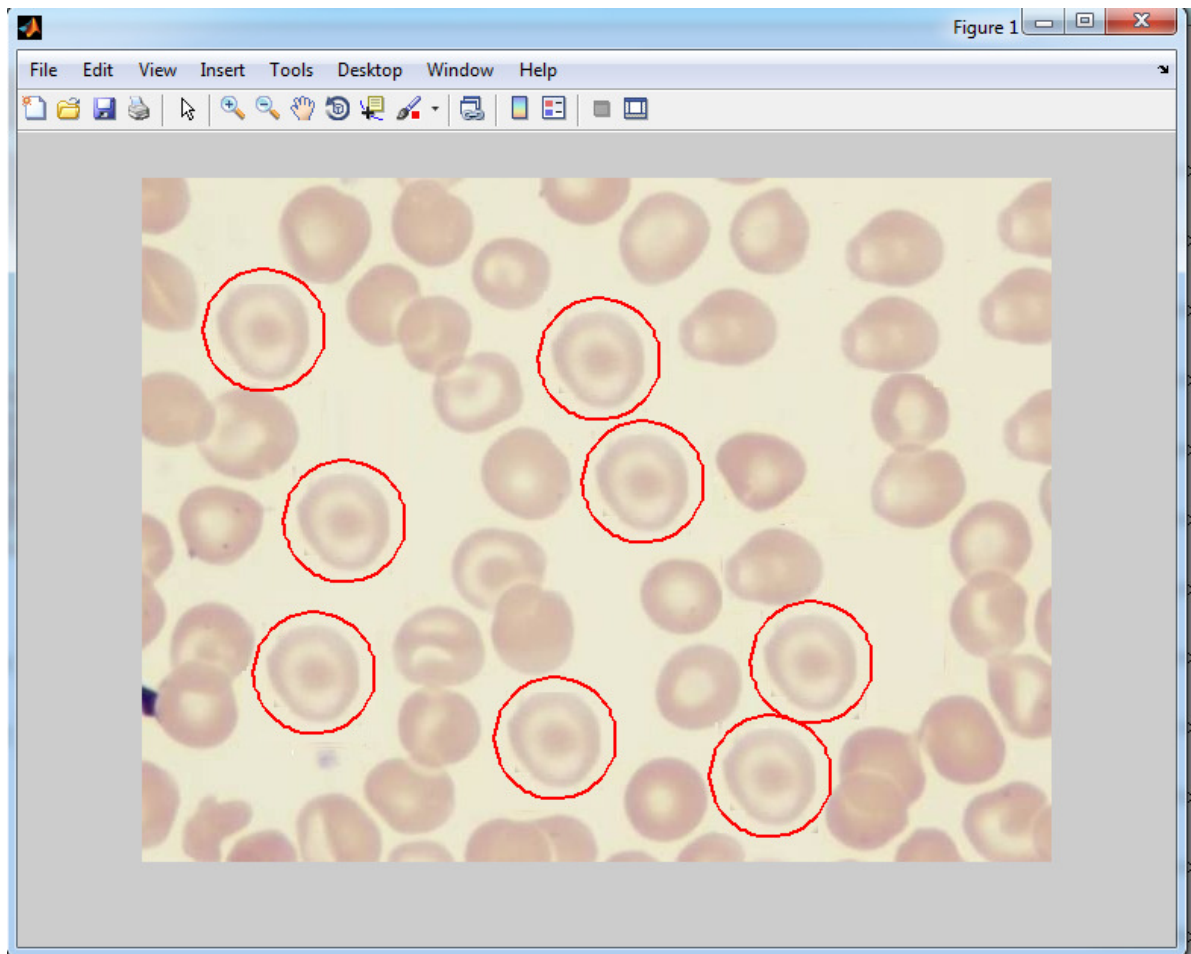


Figure (4.10) Target Cells Identification.

After applying the system to the above image sample, the system found the following results:

- The total cell count is (25)
- (Eight) Target cells with percentage (32).

These results can indicate to (iron deficiency anemia, thalassemia, and some hemoglobinopathies).

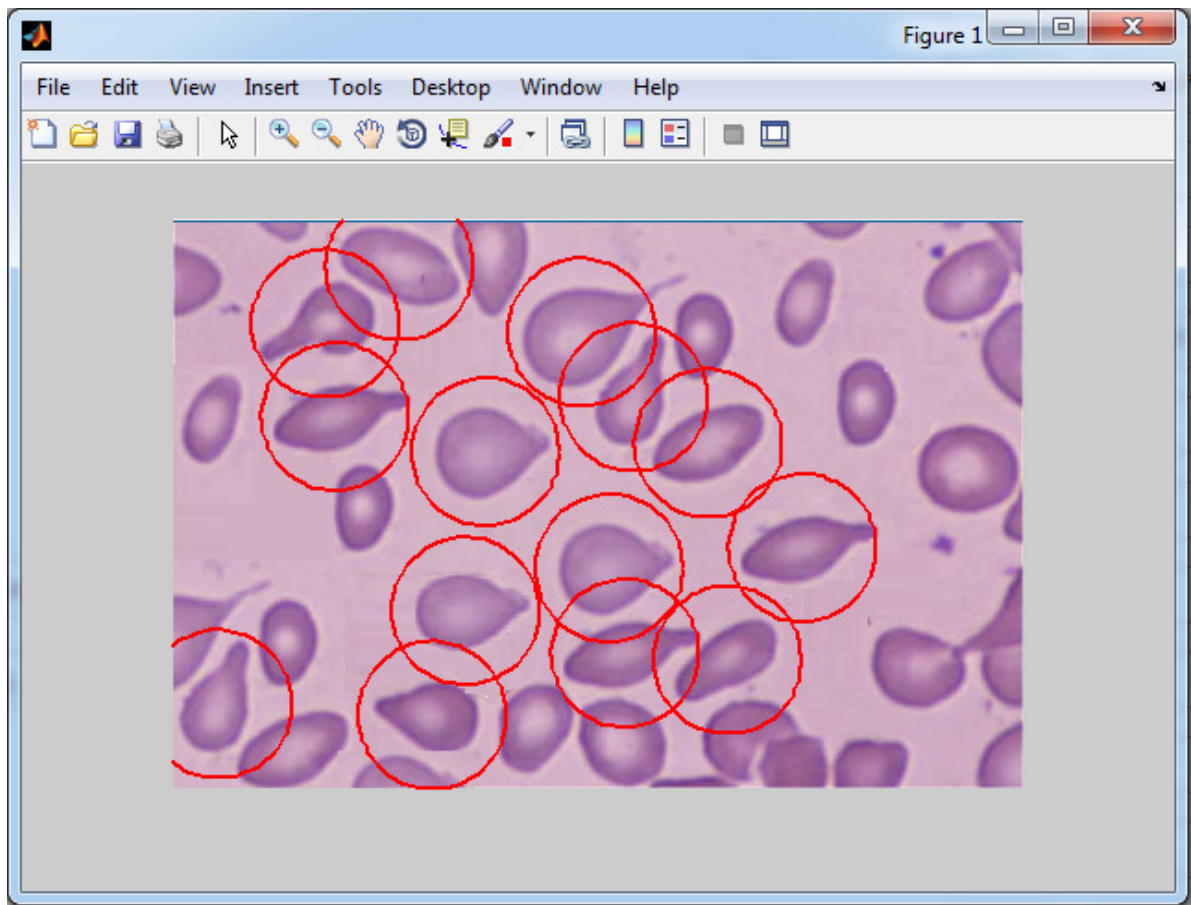


Figure (4.11) Teardrop Cells Identification.

After applying the system to the above image sample, the system found the following results:

- The total cell count is (21)
- (11) Teardrop cells with percentage (52.381 %).
- (Three) Elliptocytes with percentage (14.2857).

These results can indicate to (Hemolytic anemia, Thalassemia, Severe iron deficiency anemia).



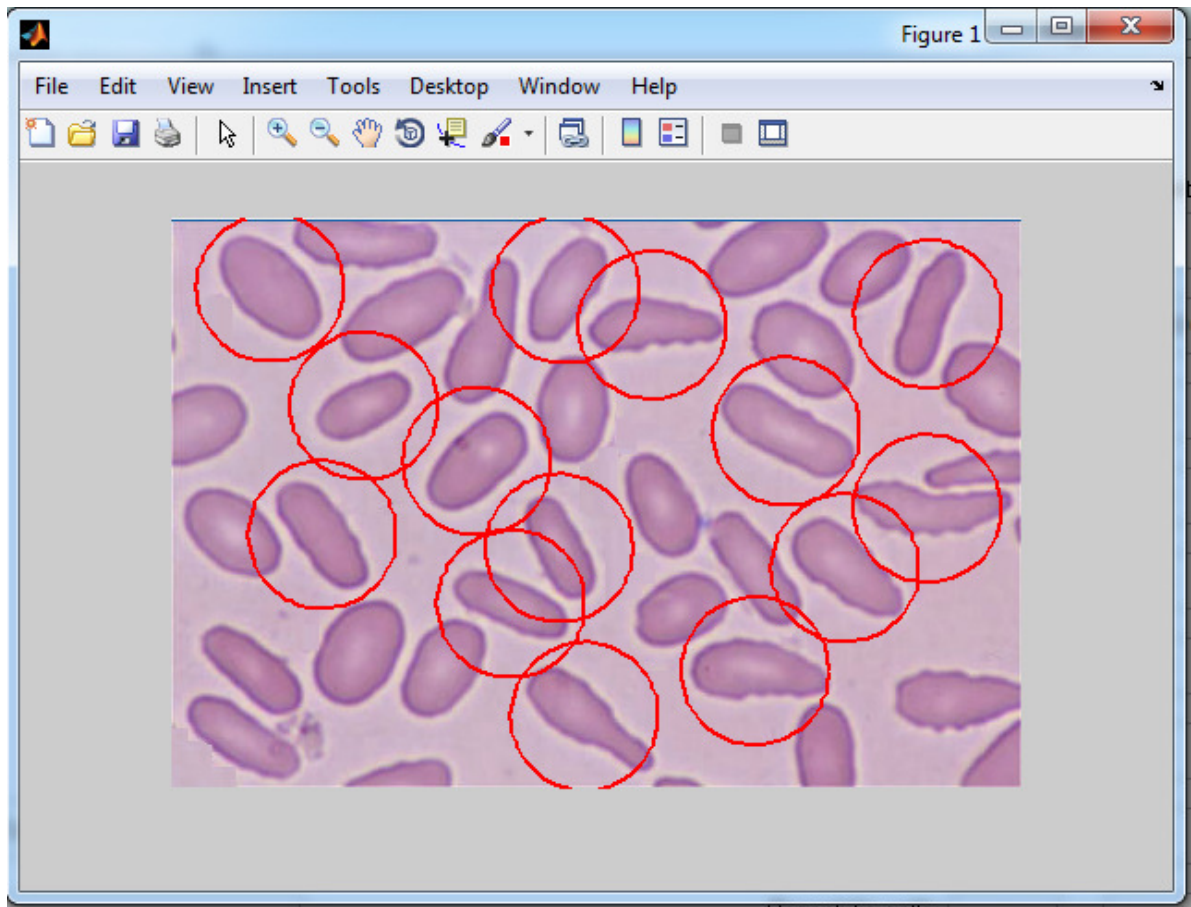


Figure (4.12) Elliptocytes Identification.

After applying the system to the above image sample, the system found the following results:

- The total cell count is (23).
- (14) Elliptocytes with percentage (60.8696).

These results can indicate to (Hereditary elliptocytosis, Iron deficiency anemia, Thalassemia, Myelodysplastic syndrome, and Megaloblastic anemia).

### 4.3 Comparison of Classification: System versus Traditional Method

The performance and the accuracy of this model is compared with the traditional method, when making comparisons between two methods applied to the same blood samples, the results were close enough and acceptably comparable.

The chart (4.1) presents the results of classifying training set for the 12 type of RBCs. in this chart the red line represents the results of traditional method and the blue line representing the system results. The chart (4.2) presents the accuracy rates whereas the blue line represents the accuracy rate for each RBCs type.

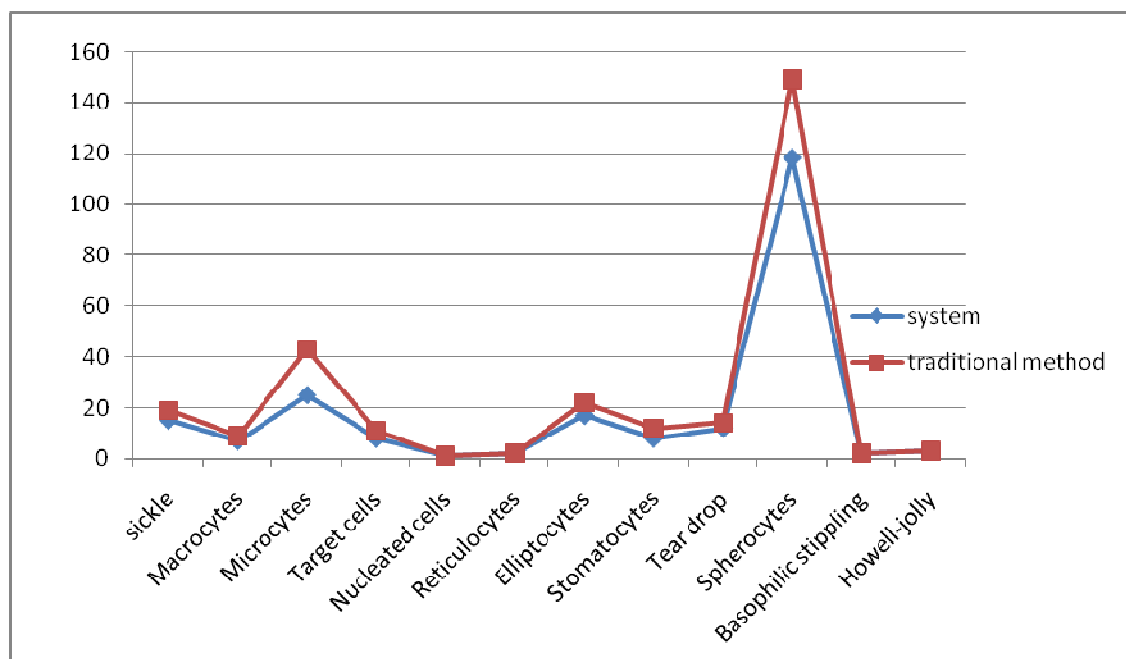


Chart (4.1) Results of Comparison for Classification between System and Traditional Method.

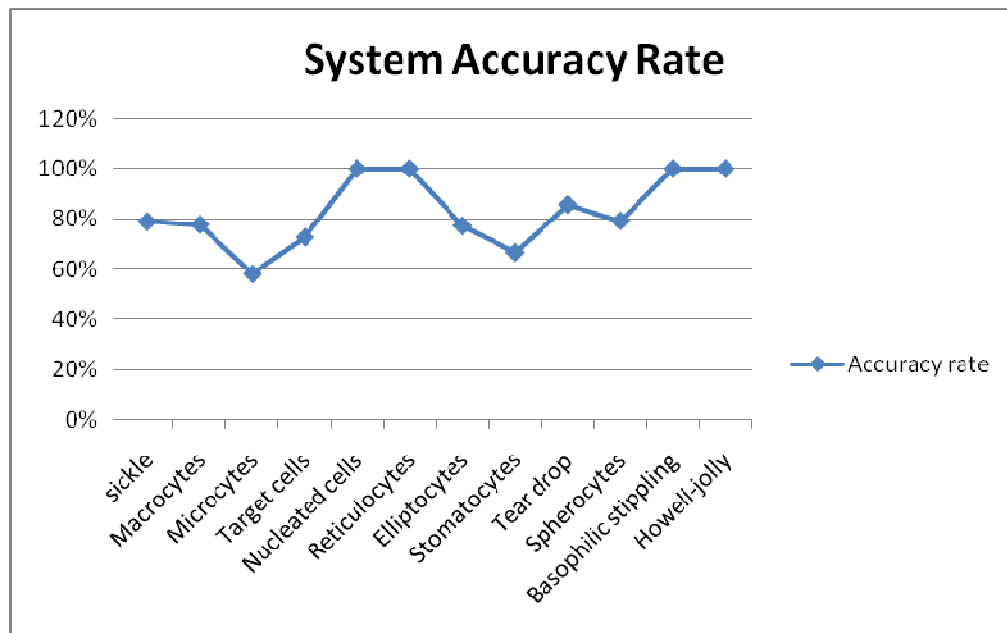


Chart (4.2) The System Accuracy Rate.

#### 4.4 Experts Point of View

The system shows an innovation of new prospect in improving anemia diagnosis; Anemia is a very common condition with varying types and associated conditions. Sick cells, spherocytes, Elliptocytes, Howell-jolly bodies, target cells and so forth could all be part of any of the various anemia syndromes. So, this wide variety of appearances can be troublesome to the inexperienced eye and time consuming to experts. A system like that provides new approach in detecting such conditions.

First, examination of blood films provides a diagnostic challenge to a variety of occupations. Medical students for instance greatly struggle to find the abnormalities in blood smears, and even if they did find any there are virtually no way of confirming their

findings. General practitioners and physicians who lack diagnostic facilities, like 24 hour available specialized labs, may find a great relief in this system. Moreover, hospitals, laboratories, hematologists, pathologist, biologic and scientific branch workers can find this system very appealing.

Second, it provides the ability to examine multiple blood-smears at once. This unique feature can attract great interest hematologists, pathologists and laboratories. A lot of hematologists can find blood smear examination time and effort consuming especially those with crowded practices. Such a system can provide quick and cost effective means of detecting abnormalities while leaving the task of confirming these results and making the final diagnosis to the assigned physician.

Lastly, this system is very easy by using a software that can be downloaded in any computer device. No previous training or complicated activating steps are required. Moreover, the system provides the opportunity to share blood smear findings among various labs or hospitals, improving the final outcome, while sparing the discomfort of having to send multiple blood samples to various hospitals or labs. Furthermore, this program provides results that lack inter-observer variability that can be found in human-examined smears. Of note, this program should not be considered as a substitute of lab workers or trained physicians, who have to confirm the detected blood smear abnormalities in order to make the correct diagnosis that fits the patient condition.

## **Chapter five**

### **Conclusion and Future Work**

This chapter includes the thesis conclusion and suggestions for future work.

#### **5.1 Conclusion**

The approach was adapted to utilize the widespread computers technologies and image processing techniques to make the analysis of blood smears more efficient; using MATLAB environment a computer – based information system with proper software was developed to analyze RGB blood smear images.

In this work the researcher has successfully identified a large number of abnormal RBCs; classification of those identified RBCs in certain types, and calculating the percentages assist the physicians to determine the associated blood anemia.

The main advantage of this approach is to gain more accuracy when analyzing blood smear, and to save time and effort which consequently reducing the cost.

There are many previous work in that field that merely concentrated on normal cells segmentation, whether white or red, without specifying their state. This system has uniquely provided means to identify RBC counts and abnormalities.

## **5.2 Future Work**

In the future, and based upon the conclusion, the same methodology could be utilized in determining other types of diseases (such as malaria, trypanosomes).

In addition, enhancement in addressing the cells at the boundaries and overlapping cells could be the gate to a proper future application of this methodology.

In the future, route adopting modern techniques with better quality digital images would certainly enhance the end results; because the error margin greatly depends on the quality of the processed digital image.

## References

- Alhadidi, B. (2012). Diagnosis of Iron Deficiency Anemia Using Image Processing Techniques. *Research Journal of Applied Sciences, Engineering and Technology*, 4(23):5144 - 5148.
- Alhadidi, B. & Fakhouri, H. N. (2008).Automation of Iron Deficiency Anemia Blue and Red Cell Number Calculating by Intestinal Villi Tissue Slide Images Enhancing and Processing. *Proceeding of the International Conference on Computer Science and Information Technology*, Aug., Singapore, 407-410
- Alhadidi, B., Zu'bi, M. & Suleiman H. (2007).Mammogram Breast Cancer Edge Detection Using Image Processing Function. *Information Technology Journal*, vol: 6, (2), 217-221.
- Anoraganingrum, D. (1999). Cell Segmentation with Median Filter and Mathematical Morphology Operation. *In Proc. Int. Conf. Image Anal.Process., Venice*, Italy, 1043–1046.
- Bruza, P. D., & Van der Weide, Th. P. (1993). The Semantics of Data Flow Diagrams, University of Nijmegen.
- Chen, P. Yan, X. &Zheng C. (2006) .Recognition of Blood and Bone Marrow Cells using Kernel-based Image Retrieval. *IJCSNS International Journal of Computer Science and Network Security* .6:29-34.

Ciesla, B. (2007). *Hematology in Practice*. Maryland.

Diggs, L. Sturm, W. D. & Bell, A. (1985). *The Morphology of Human Blood Cells*. Abbott Park, IL: Abbott Lab.

Fauci, A. S., Braunwald, E., Kasper, D. L., Hauser, S. L., Longo, D. L., Jameson, J. L. & Loscalzo, J. (2008). *Principles of Harrison's Internal Medicine*, (17<sup>th</sup> ed.). The McGraw-Hill Companies.

Gherardi, A. Bevilacqua, A. & Piccinini, F. (2011). Illumination Field Estimation through Background Detection in Optical Microscopy. ***IEEE Symposium on Computational Intelligence in Bioinformatics and Computational Biology***.

Gonzalez, R. C., Woods, R. E. & Eddins, S. L. (2004). *Digital Image Processing Using MATLAB*. New Jersey, Pearson, Prentice Hall.

Gonzalez, R. C. & Woods, R. E. (2002). *Digital Image Processing Using MATLAB*. Prentice Hall.

Hamghalam M., Motameni M. & Kelishomi A. E. (2009). Leukocyte Segmentation in Giemsa-stained Image of Peripheral Blood Smears Based on Active Contour, ***International Conference on Signal Processing Systems***, 103-106.



Hirimitugoda, Y.M. & Wijayarathna, G. (2010). Image Analysis System for Detection of Red Cell Disorder Using Artificial Neural Networks. *Journal of Bio-medical Informatics*, Sri Lanka vol.1, no 1, 35-42.

Hoffbrand, A. v. & Moss, P. A. H. (2011). *Essential Hematology* (6<sup>th</sup> Ed.) ISBN: 978-1-4051-9890-5.

Jain, B.M., Jain, A. & Srinivas, M.B (2008). A Web Based Expert System Shell for Fault Diagnosis and Control of Power System Equipment, *International Conference on Condition Monitoring and Diagnosis*, Beijing, China.

Jorda, A. R., Vanacloig, V. A. & García, G. A. (2001). A geometric Feature Set Based on Shape Description Primitives to Recognize Natural Objects. *Proceedings of the IX Spanish Symposium on Pattern Recognition and Image Analysis*, Benicasim, Spain.

Karunakar Y., Kuwadekar A. (2011). An Unparagoned Application for Red Blood Cell Counting Using Marker Controlled Watershed Algorithm for Android Mobile, *Fifth International Conference on Next Generation Mobile Applications and Services*, 100- 104.

Liao, Q. & Deng, Y. (2002). An Accurate Segmentation Method for White Blood Cell Images. *In Proc. IEEE Int. Symp. Biomed. Imag.*, Washington, DC, 245–248.

Miswan, M.F., Sharif, J.M., Ngadi M.A., Mohamad D. & Abdul Jamil M. M. (2011). An Overview: Segmentation Method for Blood Cell Disorders, ***BIOMED 2011, IFMBE Proceedings 35***, pp. 596–599.

Mohapatra S., Patra, D. & Kumar, K. (2011). Blood Microscopic Image Segmentation Using Rough Sets, ***Image Information Processing (ICIIP), 2011 International Conference on***, 1– 6.

Mu, J., Liu X.M., Kamocka M. M., Xu Z.L., Alber M. S., Rosen E.D. & Chen D. Z. (2009). Segmentation, Reconstruction, and Analysis of Blood Thrombi in 2-Photon Microscopy Images. ***22nd IEEE Symposium on Computer-Based Medical Systems (CBMS)***, Albuquerque, New Mexico, August 3-4.

Natick, M. A. (2009) “***image processing toolbox***”, the Math works, Inc. 3 Apple Hill Drive, available: <http://www.mathworks.com>.

Nguyen N., Duong A. & Vu H. (2010). A New Method for Splitting Clumped Cells in Red Blood Images, ***Second International Conference on Knowledge and Systems Engineering***, 3-8.

Nivaldo, M. D. ***Atlas of Hematology***, available: <http://www.hematologyatlas.com>.

Phukpattaranont, P. & Boonyaphiphat, P. (2006). An Automatic Cell Counting Method for a Microscopic Tissue Image from Breast Cancer. *3rd Kuala Lumpur International Conference on Biomedical, Engineering*, Springer Link.

Pitas, I. (1993). *Digital Image Processing Algorithm*. Prentice – Hall.

Rama, C. (1992). Digital Image Processing. *IEEE. Computer society Press*.

Sadeghian, F., Seman, Z., Ramli, A.R., Kahar, B.H.A., & Saripan, M. (2009). A Framework for White Blood Cell Segmentation in Microscopic Blood Images Using Digital Image Processing. *Biol. Proced. Online*, 11, pp. 196–206.

Salem, M. I. (2009). *Recognition of Potentially Malignant Cells in Epithelial Tissues Using Image Processing*, Al-balqa' Applied University, Jordan.

Savkare, S. S & Narote, S. P. (2011). Automatic Classification of Normal and Infected Blood Cells for Parasitemia Detection, *IJCSNS International Journal of Computer Science and Network Security*, VOL.11 No.2, February 2011.

Schalkoff, R. (1992). *Pattern Recognition: Statistical, Structural and Neural Approaches*. New York: Wiley.

Sharif, J.M., Miswan, M.F., Ngadi, M.A., Salam, M.S. H. & Mahadi bin Abdul Jamil, M., (2012). Red Blood Cell Segmentation Using Masking and

Watershed Algorithm: A Preliminary Study, *International Conference on Biomedical Engineering (ICOB)*, pp. 258-262.

Sheikh, H., Bin Zhu, & Micheli-Tzanakou, E. (1996). Blood Cell Identification Using Neural Networks. *Bioengineering Conference in proceedings of the 1996 IEEE Twenty-Second Annual Northeast*, 119-20.

Shi, J. & Tomasi, C. (1994). Good Features to Track. *In IEEE International Conference on Computer Vision and Pattern Recognition (CVPR 1994)*, Seattle, WA, USA, June 21-23, pp. 593-600.

Sinha, N. & Ramakrishnan, A. G. (2002). Blood Cell Segmentation Using EM Algorithm. *In Proc. Indian Conf Vision, Graphics and Image Processin*.

Turgeon, M. L. (2012). *Clinical Hematology: Theory and Procedures* (5<sup>th</sup> ed.). Florida.

Vander, L. A. (1992). *Optical Image Processing*, Wiley.

Wang, R. & McCane B. (2008). Red Blood Cell Classification Through Depth Map and Surface Feature. *International Symposium on Computer Science and Computational Technology*, 339 - 342.

Zahir, S., Chowdhury, R. & Payne, G. W. (2006). Automated Assessment of Erythrocyte Disorders Using Artificial Neural Network, *IEEE International Symposium on Signal Processing and Information Technology*, 776-80.